

# Macular thinning in prediabetes or type 2 diabetes without diabetic retinopathy

**Citation for published version (APA):**

De Clerck, E. E. B., Schouten, J. S. A. G., Berendschot, T. T. J. M., Goezinne, F., Dagnelie, P. C., Schaper, N. C., Schram, M. T., Stehouwer, C. D. A., & Webers, C. A. B. (2018). Macular thinning in prediabetes or type 2 diabetes without diabetic retinopathy: the Maastricht Study. *Acta Ophthalmologica*, 96(2), 174-182.  
<https://doi.org/10.1111/aos.13570>

**Document license:**  
TAVERNE

**DOI:**  
[10.1111/aos.13570](https://doi.org/10.1111/aos.13570)

**Document status and date:**  
Published: 01/03/2018

**Document Version:**  
Publisher's PDF, also known as Version of Record (includes final page, issue and volume numbers)

**Please check the document version of this publication:**

- A submitted manuscript is the version of the article upon submission and before peer-review. There can be important differences between the submitted version and the official published version of record. People interested in the research are advised to contact the author for the final version of the publication, or visit the DOI to the publisher's website.
- The final author version and the galley proof are versions of the publication after peer review.
- The final published version features the final layout of the paper including the volume, issue and page numbers.

[Link to publication](#)

**General rights**

Copyright and moral rights for the publications made accessible in the public portal are retained by the authors and/or other copyright owners and it is a condition of accessing publications that users recognise and abide by the legal requirements associated with these rights.

- Users may download and print one copy of any publication from the public portal for the purpose of private study or research.
- You may not further distribute the material or use it for any profit-making activity or commercial gain
- You may freely distribute the URL identifying the publication in the public portal.

If the publication is distributed under the terms of Article 25fa of the Dutch Copyright Act, indicated by the "Taverne" license above, please follow below link for the End User Agreement:

[www.tue.nl/taverne](http://www.tue.nl/taverne)


**Take down policy**

If you believe that this document breaches copyright please contact us at:

[openaccess@tue.nl](mailto:openaccess@tue.nl)

providing details and we will investigate your claim.

# Macular thinning in prediabetes or type 2 diabetes without diabetic retinopathy: the Maastricht Study

Eline E.B. De Clerck,<sup>1</sup>  Jan S.A.G. Schouten,<sup>1</sup> Tos T.J.M. Berendschot,<sup>1</sup> Fleur Goezinne,<sup>1</sup> Pieter C. Dagnelie,<sup>2,3,4</sup> Nicolaas C. Schaper,<sup>3,4,5</sup> Miranda T. Schram,<sup>3,5</sup> Coen D.A. Stehouwer<sup>3,4,5</sup> and Carroll A.B. Webers<sup>1</sup>

<sup>1</sup>University Eye Clinic Maastricht, Maastricht University Medical Center+, Maastricht, The Netherlands

<sup>2</sup>Cardiovascular Research Institute Maastricht (CARIM), Maastricht University Medical Center+, Maastricht, The Netherlands

<sup>3</sup>Department of Epidemiology, Maastricht University, Maastricht, The Netherlands

<sup>4</sup>Care and Public Health Research Institute (CAPHRI), Maastricht University, Maastricht, The Netherlands

<sup>5</sup>Department of Internal Medicine, Maastricht University Medical Center+, Maastricht, The Netherlands

## ABSTRACT.

**Purpose:** To assess macular thinning in individuals with prediabetes or type 2 diabetes without diabetic retinopathy (DM2 w/o DR) compared with individuals with normal glucose metabolism (NGM).

**Methods:** Using spectral domain optical coherence tomography (SD-OCT), we measured macular thickness in six subfields as defined by the Early Treatment Diabetic Retinopathy Study (ETDRS) in 1838 participants from The Maastricht Study, a population-based cohort study (mean age  $59 \pm 8$  years, 49% men, 1087 NGM, 279 prediabetes, 472 DM2 w/o DR). Multivariable linear regression was used to assess the association between macular thickness and glucose metabolism status.

**Results:** After adjustment for age, sex and spherical equivalent, individuals with prediabetes showed a significant decrease in pericentral superior macular thickness [ $\beta = -2.14 \mu\text{m}$  (95% confidence interval (CI):  $-4.24$  to  $-0.03$ ),  $p < 0.05$ ] compared with individuals with NGM. In individuals with DM2 w/o DR, the fovea [ $\beta = -4.05 \mu\text{m}$  (95% CI:  $-6.30$  to  $-1.79$ ),  $p < 0.001$ ] and the four pericentral quadrants (range:  $\beta = -4.64$  to  $-5.29 \mu\text{m}$ ,  $p < 0.001$ ) were significantly thinner compared with individuals with NGM. There was a significant linear trend of macular thinning with severity of glucose metabolism status in five subfields ( $p < 0.001$ ).

**Conclusion:** Macular thickness is reduced in prediabetes and a greater reduction occurs in DM2, even before DR is clinically present. About half of the thinning observed in DM2 w/o DR was already found in prediabetes. Generalized thinning of the macula could be related to thinning of the temporal side of the optic nerve head through the connecting papillo-macular bundle.

**Key words:** neurodegeneration – optical coherence tomography – retina – type 2 diabetes

Acta Ophthalmol. 2018; 96: 174–182

© 2017 Acta Ophthalmologica Scandinavica Foundation. Published by John Wiley & Sons Ltd

doi: 10.1111/aos.13570

## Introduction

Diabetic retinopathy (DR) is a severe complication of diabetes and often

goes unnoticed until visual loss occurs. The historical definition of early DR is based on the presence of microaneurysms, which can be detected by ophthalmoscopic examination.

However, in 1980, Simonsen et al. showed the predictive value of the oscillatory potential in the development of proliferative DR (Frost-Larsen et al. 1980; Simonsen 1980) and in 1986, Bresnick et al. proposed DR to primarily be a neurosensory disorder (Bresnick 1986). Also visual acuity, dark adaptation and colour vision are impaired in individuals with diabetes (Henson & North 1979; Sokol et al. 1985; Bresnick 1986; Hardy et al. 1992; Han et al. 2004a,b; Realini et al. 2004; Klemp et al. 2005; Bearnse et al. 2006; Ng et al. 2008; Vujosevic et al. 2008; Harrison et al. 2011). These early functional deficits could be related to structural changes in the retina as revealed by optical coherence tomography (OCT) in individuals with diabetes. Recent studies suggest that thinning of the neuronal layers of the retina is an early event in the pathogenesis of DR, as these retinal neurodegenerative changes occur even before microvascular lesions can be detected with funduscopy (Barber et al. 1998; Carrasco et al. 2007, 2008; Garcia-Ramirez et al. 2009; De Clerck et al. 2015). Therefore, DR has recently been redefined as ‘structural and functional changes in the retina due to diabetes’ (Gardner et al. 2011).

Recently, we observed a linear trend of retinal nerve fibre layer (RNFL) thinning around the optic nerve head with worsening of glucose regulation, predominantly at the temporal side of

the optic nerve head (De Clerck et al. 2017). One can hypothesize that also in the macula, retinal neurodegeneration is already present in prediabetes, a stage of glucose dysregulation that occurs before type 2 diabetes. However, population-based studies of macular thickness and glucose metabolism are not available. Establishing changes in macular thickness in individuals with prediabetes and in individuals with DM2 w/o DR could open new perspectives for understanding the early pathogenesis of DR.

The aim of this study was to evaluate to what extent macular thinning occurs in individuals with DM2 w/o DR and also in individuals with prediabetes, as compared to individuals with NGM in a large population-based cohort study.

## Materials and Methods

### Study population and design

In this study, we used data from The Maastricht Study, an observational prospective population-based cohort study. The rationale and methodology have been described previously (Schram et al. 2014). In brief, the study focuses on the aetiology, pathophysiology, complications and comorbidities of DM2 and is characterized by an extensive phenotyping approach. Eligible for participation were all individuals aged between 40 and 75 years and living in the southern part of The Netherlands. Participants were recruited through mass media campaigns and from the municipal registries and the regional Diabetes Patient Registry via mailings. Recruitment was stratified according to known DM2 status for reasons of efficiency. This report includes cross-sectional data from the first 3451 participants, who completed the baseline survey between November 2010 and September 2013. The examinations of each participant were performed within a time window of 3 months. The study has been approved by the institutional medical ethical committee (NL31329.068.10) and the Minister of Health, Welfare and Sports of The Netherlands, on the basis of the Health Council's opinion (Permit 131088-105234-PG) and is compliant with the tenets of the Declaration of Helsinki.

All participants gave written informed consent.

### Glucose metabolism status

To determine glucose metabolism status, all participants, except those who used insulin, underwent a standardized 2-hr 75 g oral glucose tolerance test (OGTT) after an overnight fast. For safety reasons, participants with a fasting glucose level above 11.0 mmol/l, as determined by a finger prick, did not undergo the OGTT. For these individuals ( $n = 13$ ), fasting glucose level and information about diabetes medication were used to determine glucose metabolism status. Glucose metabolism status was defined according to the WHO (2006) criteria into NGM, impaired fasting glucose (IFG), impaired glucose tolerance (IGT), prediabetes (i.e. IFG and/or IGT) and DM2 (2006). For this study, individuals with DM1, individuals with latent autoimmune diabetes of adults, steroid-induced diabetes and individuals who underwent a pancreas transplantation were excluded.

### Ophthalmologic measurements

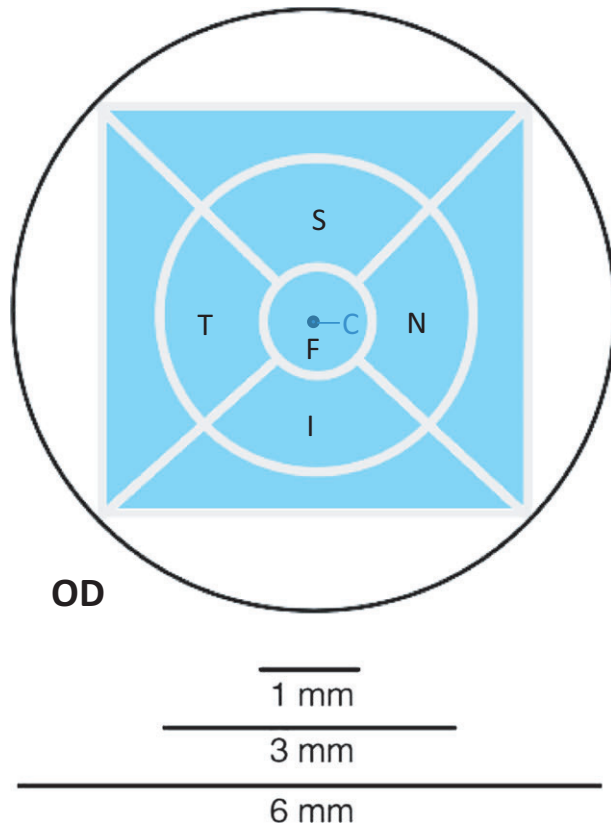
Automated refraction was performed in both eyes using an automated refractor (Tonoref II; Nidek, Gamagori, Japan). Once the pupils were dilated with tropicamide 0.5% and phenylephrine 2.5%, fundus photography of both eyes was performed. All fundus photographs were made with an auto fundus camera (Model AFC-230; Nidek) in 45 degrees of at least three fields: one field centred on the optic disc, one field centred on the macula and one temporal field positioned one disc-diameter from the centre of the macula. Diabetic retinopathy (DR) was graded according to the DR Disease Severity Scale and International Clinical DR Disease Severity Scale (American Academy of Ophthalmology Retina/Vitreous Panel 2014). Next, all participants were examined with the Spectralis OCT (Heidelberg Engineering, Heidelberg, Germany, Heidelberg Eye Explorer software version 5.7.5.0) with the eye tracking function enabled. A macular volume scan (17 ART, 73 sections, 60  $\mu\text{m}$ ) was performed in both eyes by experienced examiners masked to the conditions of the participants.

Regional numeric data of the macular thickness were derived from the Macular Thickness Map (Massin et al. 2002). With use of the Macular Thickness Map, macular thickness was measured at the centre, the fovea and in the four pericentral subfields as defined by ETDRS (Fig. 1). The cross-sections of the macular volume scans were reviewed and scored for the presence of cysts by two experienced graders in a masked fashion based on a prespecified protocol. Individuals with an incomplete volume scan (<73 sections), poor quality imaging (signal-to-noise ratio <20 dB), unsatisfactory automatic real-time tracking (<15) and retinal disorders (i.e. epiretinal membrane, cysts, DR or previous laser treatment) were excluded.

Reproducibility was assessed by two observers in both eyes of nine individuals (seven men,  $56.0 \pm 5.5$  years; four individuals with DM2) who were examined on two occasions spaced 1 week apart. The intra-observer and interobserver intraclass correlation coefficients were  $\geq 0.99$  for all macular thicknesses in both eyes.

### Statistical analysis

Statistical analysis was performed in SPSS Statistics 23 for Windows (SPSS, IBM, Armonk, NY, USA). Differences between group characteristics were tested using one-way analysis of variance (ANOVA) for continuous variables and chi-squared tests for categorical variables. Multivariable linear regression was used to analyse the association between glucose metabolism status (prediabetes and DM2 w/o DR; determinant) and macular thickness (outcome). We combined the categories IFG and IGT into prediabetes, because analyses did not show differences between IFG and IGT (data not shown). First, a crude analysis was performed. Next, associations were adjusted for age, sex and spherical equivalent by adding these variables as covariates to the model. Interactions between age, sex, spherical equivalent and glucose metabolism status were tested. The results were expressed as regression coefficients ( $\beta$ ), representing the mean difference in macular thickness as compared with individuals with NGM, with their 95% CIs. A  $p$  value <0.05 was considered statistically significant.



**Fig. 1.** Illustration of the region in the ETDRS grid from which data were gathered for the volume scan in a right eye. The blue area represents the area from which data were gathered. The two regions in the centre constitute the central macula. The four regions around the fovea constitute the pericentral macula. Point C = centre thickness, Region F = foveal thickness, Region I = pericentral inferior macular thickness, Region N = pericentral nasal macular thickness, Region, S = pericentral superior macular thickness, Region T = pericentral temporal macular thickness.

**Results**

**General characteristics**

Figure 2 shows the flow diagram of the study. From December 2011 to


September 2013, 2363 participants from The Maastricht Study underwent OCT measurement. Forty-one participants with DM1 or other types of diabetes were excluded. Participants with an incomplete volume scan

(*n* = 161) or an unsatisfactory quality of measurement (*n* = 5) were also excluded. In addition, individuals with retinal disorders (*n* = 160) were excluded –that is epiretinal membrane (*n* = 92), cysts (*n* = 42), DR (*n* = 40) and/or previous laser treatment (*n* = 18). We additionally excluded individuals where data on the spherical equivalent were missing (*n* = 158). Thus, 1838 participants were available for analysis with adjustment for age, sex and spherical equivalent. Participants who were excluded due to missing values were more likely to be older ( $60 \pm 8$  versus  $59 \pm 8$  years,  $p < 0.01$ ), to be male (54% versus 49% men,  $p < 0.01$ ) and to have a lower spherical equivalent ( $-0.60 \pm 2.92$  versus  $-0.27 \pm 2.49$  D,  $p < 0.01$ ).

Of the 1838 participants, 1087 participants had NGM (59.1%), 279 participants had prediabetes (15.2%), and 472 participants had DM2 w/o DR (25.7%). Differences in characteristics among these three groups are shown in Table 1.

**Macular thickness**

Table 2 shows crude associations between glucose metabolism status and centre thickness, foveal thickness and the four pericentral macular thicknesses. In individuals with NGM, mean macular thicknesses were as follows: centre thickness  $233.4 \mu\text{m}$  (95% CI: 232.2–234.6), foveal thickness  $284.5 \mu\text{m}$  (95% CI: 283.2–285.7), pericentral nasal macular thickness



**Fig. 2.** Flow diagram of the study. DM2 w/o DR = type 2 diabetes mellitus without diabetic retinopathy, NGM = normal glucose metabolism, OCT = optical coherence tomography.

**Table 1.** Baseline characteristics of the study population, stratified by glucose metabolism status.

	NGM (N = 1087)	Prediabetes (N = 279)	DM2 w/o DR (N = 472)	p-value (Prediabetes versus NGM)	p-value (DM2 w/o DR versus NGM)
Age (years), mean (SD)	57.7 (8.0)	60.8 (7.4)	62.3 (7.8)	<0.001	<0.001
Male sex, n (%)	441 (40.6)	149 (53.4)	307 (65.0)	<0.001	<0.001
Spherical equivalent (D), mean (SD)	-0.42 (2.48)	-0.18 (2.48)	0.04 (2.49)	0.16	<0.01
Diabetes duration (years), median (IQR)*	-	-	4.0 (0.0–8.0)	-	-

D = dioptre, DM2 w/o DR, type 2 diabetes without diabetic retinopathy, IQR = interquartile range, NGM = normal glucose metabolism, SD = standard deviation.

\* Available for 363 participants with DM2.

**Table 2.** Mean difference of macular thickness between individuals with prediabetes and type 2 diabetes without diabetic retinopathy versus normal glucose metabolism adjusted for age, sex and spherical equivalent.

	Crude analysis			Adjustment for age, sex, and spherical equivalent		
	Prediabetes $\beta$ (95% CI)	DM2 w/o DR $\beta$ (95% CI)	Trend p	Prediabetes $\beta$ (95% CI)	DM2 w/o DR $\beta$ (95% CI)	Trend p
Center thickness ( $\mu\text{m}$ )	-0.67 (-3.44 to 2.11)	-0.48 (-2.75 to 1.80)	0.64	-1.20 (-3.96 to 1.55)	-1.65 (-4.00 to 0.69)	0.15
Foveal thickness ( $\mu\text{m}$ )	-0.93 (-3.67 to 1.82)	-1.06 (-3.32 to 1.20)	0.33	-2.48 (-5.13 to 0.17)	<b>-4.05 (-6.30 to -1.79)*</b>	<0.001
Pericentral nasal macular thickness ( $\mu\text{m}$ )	<b>-2.47 (-4.60 to -0.34)*</b>	<b>-5.16 (-6.90 to -3.41)*</b>	<0.001	-1.92 (-4.02 to 0.18)	<b>-4.64 (-6.43 to -2.85)*</b>	<0.001
Pericentral superior macular thickness ( $\mu\text{m}$ )	<b>-2.90 (-5.02 to -0.78)*</b>	<b>-6.20 (-7.94 to -4.45)*</b>	<0.001	<b>-2.14 (-4.24 to -0.03)*</b>	<b>-5.29 (-7.08 to -3.50)*</b>	<0.001
Pericentral temporal macular thickness ( $\mu\text{m}$ )	-1.90 (-3.91 to 0.11)	<b>-4.78 (-6.43 to -3.12)*</b>	<0.001	-1.64 (-3.62 to 0.34)	<b>-4.76 (-6.44 to -3.07)*</b>	<0.001
Pericentral inferior macular thickness ( $\mu\text{m}$ )	<b>-2.31 (-4.43 to -0.18)*</b>	<b>-5.46 (-7.21 to -3.72)*</b>	<0.001	-1.59 (-3.68 to 0.51)	<b>-4.67 (-6.45 to -2.89)*</b>	<0.001

$\beta$  = regression coefficient, 95% CI = 95% confidence interval, DM2 w/o DR = type 2 diabetes without diabetic retinopathy, p = p-value for linear trend.

\* Boldface values indicate  $p < 0.05$ .

350.4  $\mu\text{m}$  (95% CI: 349.4–351.3), pericentral superior macular thickness 347.3  $\mu\text{m}$  (95% CI: 346.4–348.3), pericentral temporal macular thickness 336.1  $\mu\text{m}$  (95% CI: 335.2–337.0) and pericentral inferior macular thickness 345.0  $\mu\text{m}$  (95% CI: 344.0–345.9). All pericentral macular thickness values were significantly lower in individuals with prediabetes and in individuals with DM2 w/o DR compared with individuals with NGM ( $p < 0.05$ ), except for the pericentral temporal macular thickness in individuals with prediabetes ( $p = 0.06$ ). The mean macular thicknesses of the right eye were very similar to the mean macular thicknesses of the left eye (data not shown).

Figure 3 shows crude pericentral macular thicknesses according to glucose metabolism status. Thinning of

the macula was more pronounced with worsening of glucose metabolism status, with a highly significant p-value for linear trend for all quadrants ( $p < 0.001$ ).

Age was significantly associated with macular thinning of all pericentral macular thicknesses (range:  $\beta = -0.33$  to  $-0.41$  per 1 year of age,  $p < 0.001$ ). In women, all macular thicknesses were thinner compared with men, especially at the fovea (range:  $\beta = -1.03$  to  $-12.22$   $\mu\text{m}$ ,  $p \leq 0.01$ ). Macular thinning in women was not significant in the superior quadrant ( $\beta = -1.03$ ,  $p = 0.18$ ). Per dioptre decrease in spherical equivalent, the pericentral macular thickness was 0.16–0.19  $\mu\text{m}$  thinner. However, the association between spherical equivalent and macular thickness was not significant

( $p > 0.05$ ). In individuals with DM2 w/o DR, the four pericentral quadrants were significantly associated with duration of diabetes (range:  $\beta = -0.36$  to  $-0.42$   $\mu\text{m}$  per 1 year of duration,  $p < 0.05$ ).

Table 2 also shows associations adjusted for age, sex and spherical equivalent between glucose metabolism status and centre thickness, foveal thickness and the four pericentral macular thicknesses. After adjustment for age, sex and spherical equivalent, individuals with prediabetes showed a statistically significant decrease in pericentral superior macular thickness [ $\beta = -2.14$   $\mu\text{m}$  (95% CI:  $-4.24$  to  $-0.03$ ),  $p < 0.05$ ] compared with individuals with NGM. In individuals with DM2 w/o DR, the fovea and the four pericentral quadrants were significantly



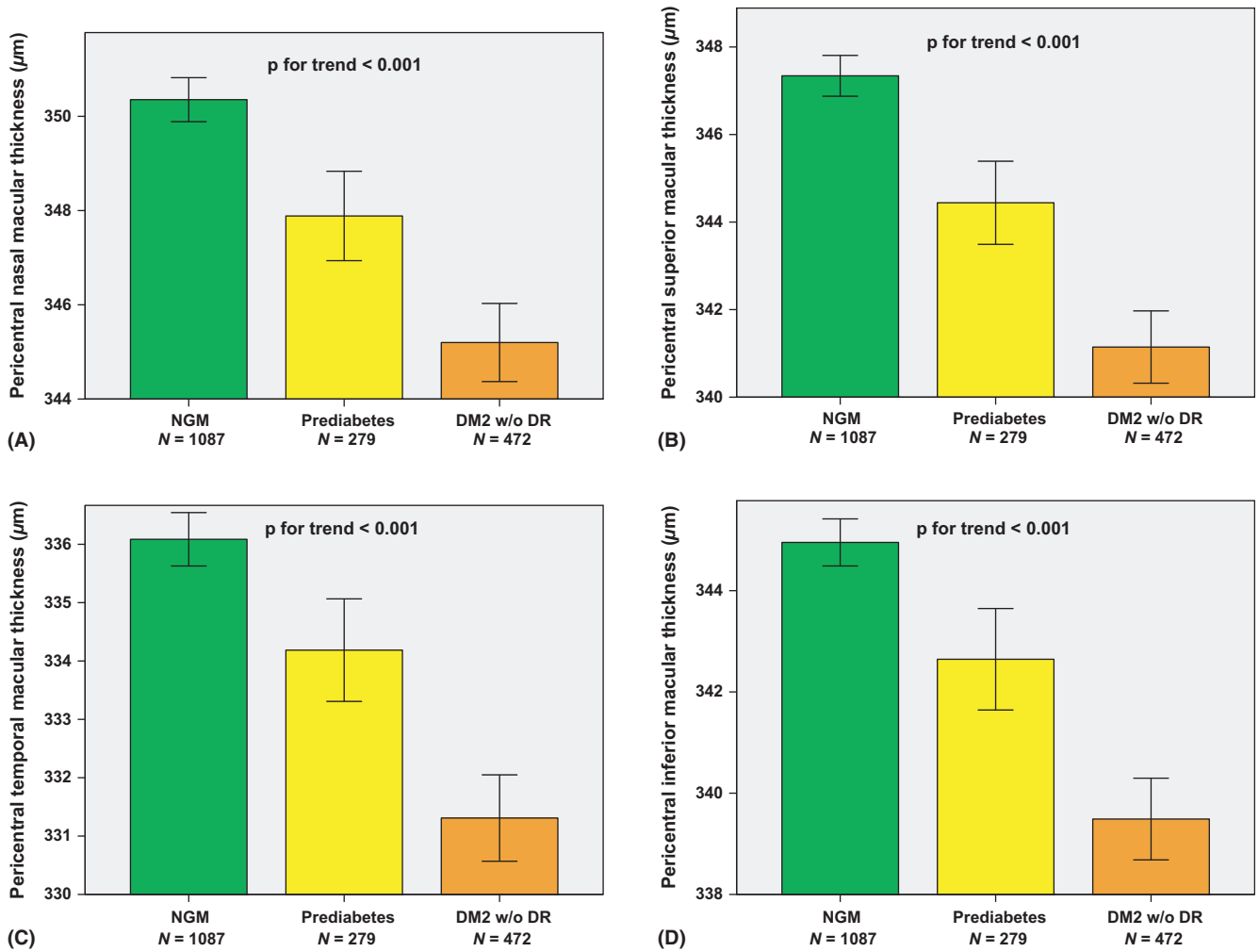


Fig. 3. Crude pericentral nasal macular thickness (A), pericentral superior macular thickness (B), pericentral temporal macular thickness (C) and pericentral inferior macular thickness (D) for individuals with NGM, prediabetes and DM2 (Mean ± SE). DM2 w/o DR = type 2 diabetes without diabetic retinopathy, NGM = normal glucose metabolism.

thinner compared with individuals with NGM (range:  $\beta = -4.05$  to  $-5.29 \mu\text{m}$ ,  $p < 0.001$ ). All macular thicknesses decreased with worsening of glucose metabolism status, with a significant p-value for linear trend for the fovea and the pericentral macular thicknesses ( $p < 0.001$ ). There were no statistically significant interactions between the variables age, sex, spherical equivalent and glucose metabolism status ( $p > 0.10$ ). These interaction terms were, therefore, left out of the models.

Figure 4 shows the mean difference ( $\beta$ ) in pericentral macular thicknesses in individuals with prediabetes and DM2 w/o DR as compared with NGM after adjustment for age, sex and spherical equivalent. About half of the thinning observed in DM2 w/o DR was already found in prediabetes. Thinning of the macula was more pronounced with worsening of glucose

metabolism status, with a significant linear trend for all quadrants ( $p < 0.001$ ).

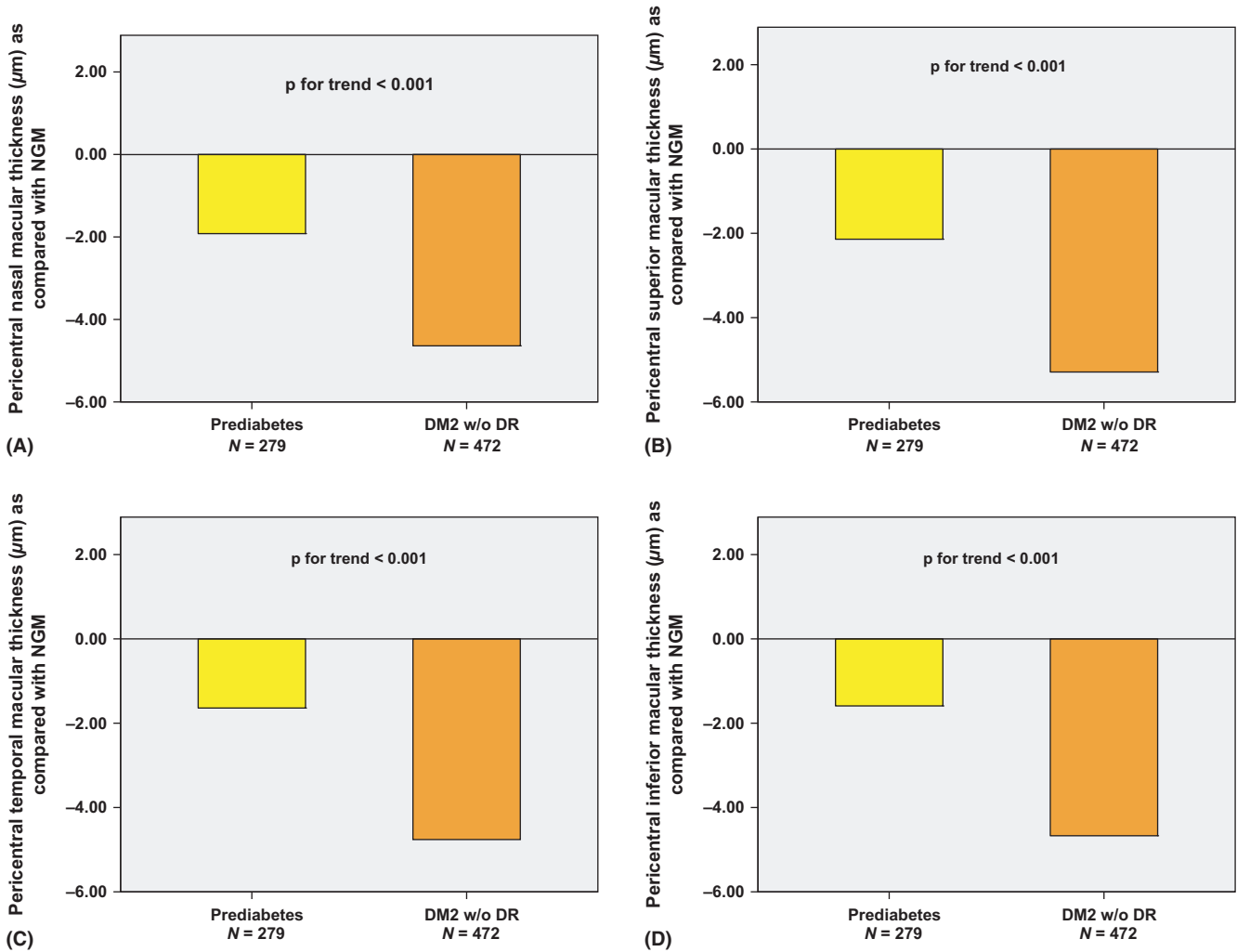
### Discussion

We show for the first time that prediabetes and further worsening of glucose metabolism status are associated with general thinning of the macula in a population-based setting. About half of the thinning observed in DM2 w/o DR was already found in prediabetes. These findings suggest that early neurodegenerative changes are already present in prediabetes, and that these changes are more evident in individuals with DM2 w/o DR in all subfields.

To our knowledge, this is the first study on the association between glucose metabolism status, as defined by an OGTT, and changes in macular thickness. In contrast to previous

studies, we used a highly detailed volume scan consisting of 73 B-scans with an excellent inter- and intra-observer reliability to assess the macular thickness. The mean macular thicknesses of all subfields had a small standard error and were very similar between right and left eyes. In individuals with NGM, the pericentral temporal macula was thinner than the other quadrants, which is also similar to previous studies (Sanchez-Tocino et al. 2002; Sugimoto et al. 2005; Browning et al. 2008; Oshitari et al. 2009). Thinning of the different pericentral macular subfields is consistent with two previous studies using OCT in individuals with DM2 w/o DR (Sugimoto et al. 2005; Oshitari et al. 2009).

We found a highly significant trend of macular thinning from NGM via prediabetes to DM2 w/o DR in all pericentral subfields of both eyes.



**Fig. 4.** Mean difference in pericentral nasal macular thickness (A), pericentral superior macular thickness (B), pericentral temporal macular thickness (C) and pericentral inferior macular thickness (D) in individuals with prediabetes and DM2 w/o DR as compared with individuals with NGM after adjustment for age, sex and spherical equivalent. DM2 w/o DR = type 2 diabetes without diabetic retinopathy, NGM = normal glucose metabolism.

Previous studies also assessed the macular thickness in individuals with DM2 w/o DR. However, these studies showed discrepancies in results regarding centre thickness, foveal thickness and pericentral macular thicknesses (De Clerck et al. 2015). These discrepancies may be explained by heterogeneity among these studies in terms of sample size, population characteristics and scan protocol. In addition, none of these studies made adjustments for basic confounding factors such as age, sex and spherical equivalent. Similar to previous studies, we found that ageing is associated with macular thinning (Massin et al. 2002; Sanchez-Tocino et al. 2002; Chan et al. 2006; von Hanno et al. 2017). We detected a thinner macular thickness in women compared with men. This has also been described previously (Massin et al.

2002; Chamberlain et al. 2006; von Hanno et al. 2017). Controversial results have been reported for the association between spherical equivalent and macular thickness (Zou et al. 2006; Lam et al. 2007; Ooto et al. 2010, 2011; von Hanno et al. 2017). We found a non-significant association between a lower spherical equivalent and macular thinning. Our findings regarding the negative correlation between macular thickness and diabetes duration in individuals with type 2 diabetes correspond with previous research in individuals with type 1 diabetes (Sohn et al. 2016).

Macular thinning seems to reflect early neurodegenerative changes in diabetes. Therefore, our findings support the hypothesis that retinal neurodegenerative changes occur before the presence of microvascular changes

as assessed with conventional techniques (Friedenwald 1950; Cogan et al. 1961; Barber 2003) and even before the diagnosis of DM2. Previous studies have shown that chronic hyperglycaemia, oxidative stress and accumulation of advanced glycation end products result in an increase in the concentration of glutamate and the loss of neuroprotective factors. Animal studies (Lieth et al. 1998; Barber et al. 2000, 2005; Rungger-Brandle et al. 2000; Zeng et al. 2000; Kim et al. 2004; Martin et al. 2004; Gastinger et al. 2006; Tang et al. 2011; Bogdanov et al. 2014; Arroba et al. 2016) and human studies (Wolter 1961; Bloodworth 1962; Barber et al. 1998; Mizutani et al. 1998; Abu-El-Asrar et al. 2004) have demonstrated that these insults can result in glial activation, neuronal apoptosis, thinning of the

neuronal layers in the retina and an increase in vascular endothelial growth factor. This leads to vasoregression, an impaired hemodynamic response and a breakdown of the blood-retinal barrier, resulting in early microvascular changes, and in a later stage to accumulation of extravascular fluid, which can result in cystoid macular oedema (Cunha-Vaz et al. 1975; Simonett et al. 2017). Finally, inflammatory factors and a low number or dysfunction of endothelial progenitor cells also play a role in these microvascular and neurodegenerative changes (Simo & Hernandez 2014).

In prediabetes and DM2 w/o DR, we observed macular thinning in all subfields, whereas in the RNFL around the optic nerve head, only the temporal half was affected in our earlier study in the same population (De Clerck et al. 2017). This may be explained by damage to the papillo-macular bundle and its neighbouring bundles emanating from ganglion cells all over the macula, together with their axons, forming nerve fibre bundles predominantly connected with the temporal RNFL around the optic nerve head (Lee et al. 2012). This thinning reflects a decrease in the number of retinal nerve fibres and ganglion cells (van Dijk et al. 2010; Kim et al. 2015). Ganglion cells are sensitive to oxidative stress and to diabetes-related neurodegenerative changes (Kergoat et al. 2006; Kern & Barber 2008). Retinal nerve fibre layer (RNFL) thinning around the optic nerve head and macular thinning could occur secondary to neuronal apoptosis by metabolic stress or alterations in the nerve fibre connections between the optic nerve head and the macula. Furthermore, parvocellular axons from the papillo-macular bundle are more sensitive to early metabolic changes (Stricker et al. 2011).

A previous study showed preferential thinning of the inner retinal layers in individuals with type 2 diabetes (van Dijk et al. 2012). Recent studies suggest that there is a direct relationship between axonal loss and visual function, as a decrease in ganglion cells and their axons, as measured by SD-OCT, is related to visual field loss in individuals with glaucoma (Bogunovic et al. 2015). Therefore, macular ganglion cell parameters are not only affected in individuals with diabetes, but also seem to be more appropriate for the

diagnosis of glaucoma than measuring the RNFL thickness around the optic nerve head (Kim et al. 2011; Moreno et al. 2011; Rimayanti et al. 2014; Ng et al. 2015).

Neurodegenerative macular thinning in prediabetes suggests that DR begins in the earliest stages of glucose dysregulation, early in the progression from NGM to frank diabetes, which lasts 7 years on average (Ramlo-Halsted & Edelman 1999). This is an important finding as glucose dysregulation is amenable to treatment and may thus be a target to prevent neurodegenerative changes in the retina in DM2. Early identification, lifestyle modification and treatment of cardiovascular risk factors in individuals with prediabetes have the potential to reduce both the incidence of diabetes and the DR (McKinlay & Marceau 2000; Olafsdottir et al. 2016; Larsen et al. 2017). Therefore, the first step may be to identify prediabetes rather than focusing on detecting microvascular changes using ophthalmoscopy to reduce the burden of diabetes on ocular changes, whether neuronal and (or) vascular.

Due to the later implementation of the OCT measurements, it is possible that our sample is not truly population-based. The missing participants, however, were older, suggesting that, if anything, macular thinning in the total study population of the Maastricht Study is expected to be greater than reported here. This study has a cross-sectional design and does not allow conclusions on cause-and-effect relations. However, by comparing individuals with NGM, prediabetes and DM2 w/o DR, we simulate the pathological pathway of glucose metabolism deterioration.

Future studies should focus on causality and underlying mechanisms of macular thinning in prediabetes and DM2 and should also quantify the thickness of the separate layers of the retina, because these layers can be affected differently by diabetes (van Dijk et al. 2012). In addition, the link between these structural changes and functional changes, such as visual field loss, needs to be studied further. Moreover, future studies should assess whether neurodegenerative changes in the macula are related to the presence of neuropathy and nephropathy in individuals with prediabetes and DM2.

In conclusion, macular thickness is reduced in prediabetes and a greater reduction occurs in DM2, even before DR is clinically present. About half of the thinning observed in DM2 w/o DR was already found in prediabetes. Generalized thinning of the macula could be related to thinning of the temporal side of the optic nerve head through the connecting papillo-macular bundle.

## References

- Abu-El-Asrar AM, Dralands L, Missotten L, Al-Jadaan IA & Geboes K (2004): Expression of apoptosis markers in the retinas of human subjects with diabetes. *Invest Ophthalmol Vis Sci* **45**: 2760–2766.
- American Academy of Ophthalmology Retina/Vitreous Panel. Preferred Practice Pattern® Guidelines (2014): Diabetic retinopathy. San Francisco, CA: American Academy of Ophthalmology. Available at: [www.aao.org/ppp](http://www.aao.org/ppp). (Accessed on 12 Aug 2015).
- Arroba AI, Mazzeo A, Cazzoni D, Beltramo E, Hernandez C, Porta M, Simo R & Valverde AM (2016): Somatostatin protects photoreceptor cells against high glucose-induced apoptosis. *Mol Vis* **22**: 1522–1531.
- Barber AJ (2003): A new view of diabetic retinopathy: a neurodegenerative disease of the eye. *Prog Neuropsychopharmacol Biol Psychiatry* **27**: 283–290.
- Barber AJ, Lieth E, Khin SA, Antonetti DA, Buchanan AG & Gardner TW (1998): Neuronal apoptosis in the retina during experimental and human diabetes. Early onset and effect of insulin. *J Clin Invest* **102**: 783–791.
- Barber AJ, Antonetti DA & Gardner TW (2000): Altered expression of retinal occludin and glial fibrillary acidic protein in experimental diabetes. The Penn State Retina Research Group. *Invest Ophthalmol Vis Sci* **41**: 3561–3568.
- Barber AJ, Antonetti DA, Kern TS et al. (2005): The Ins2Akita mouse as a model of early retinal complications in diabetes. *Invest Ophthalmol Vis Sci* **46**: 2210–2218.
- Bearse MA Jr, Adams AJ, Han Y, Schneck ME, Ng J, Bronson-Castain K & Barez S (2006): A multifocal electroretinogram model predicting the development of diabetic retinopathy. *Prog Retin Eye Res* **25**: 425–448.
- Bloodworth JM Jr (1962): Diabetic retinopathy. *Diabetes* **11**: 1–22.
- Bogdanov P, Corraliza L, Villena JA et al. (2014): The db/db mouse: a useful model for the study of diabetic retinal neurodegeneration. *PLoS ONE* **9**: e97302.
- Bogunovic H, Kwon YH, Rashid A, Lee K, Critser DB, Garvin MK, Sonka M & Abramoff MD (2015): Relationships of retinal structure and Humphrey 24-2 visual field thresholds in patients with glaucoma. *Invest Ophthalmol Vis Sci* **56**: 259–271.



- Bresnick GH (1986): Diabetic retinopathy viewed as a neurosensory disorder. *Arch Ophthalmol* **104**: 989–990.
- Browning DJ, Fraser CM & Clark S (2008): The relationship of macular thickness to clinically graded diabetic retinopathy severity in eyes without clinically detected diabetic macular edema. *Ophthalmology* **115**: 533–539.e532.
- Carrasco E, Hernandez C, Miralles A, Huguet P, Farres J & Simo R (2007): Lower somatostatin expression is an early event in diabetic retinopathy and is associated with retinal neurodegeneration. *Diabetes Care* **30**: 2902–2908.
- Carrasco E, Hernandez C, de Torres I, Farres J & Simo R (2008): Lowered cortistatin expression is an early event in the human diabetic retina and is associated with apoptosis and glial activation. *Mol Vis* **14**: 1496–1502.
- Chamberlain MD, Guymer RH, Dirani M, Hopper JL & Baird PN (2006): Heritability of macular thickness determined by optical coherence tomography. *Invest Ophthalmol Vis Sci* **47**: 336–340.
- Chan A, Duker JS, Ko TH, Fujimoto JG & Schuman JS (2006): Normal macular thickness measurements in healthy eyes using Stratus optical coherence tomography. *Arch Ophthalmol* **124**: 193–198.
- Cogan DG, Toussaint D & Kuwabara T (1961): Retinal vascular patterns. IV. Diabetic retinopathy. *Arch Ophthalmol* **66**: 366–378.
- Cunha-Vaz J, Faria de Abreu JR & Campos AJ (1975): Early breakdown of the blood-retinal barrier in diabetes. *Br J Ophthalmol* **59**: 649–656.
- De Clerck EE, Schouten JS, Berendschot TT et al. (2015): New ophthalmologic imaging techniques for detection and monitoring of neurodegenerative changes in diabetes: a systematic review. *Lancet Diabetes Endocrinol* **3**: 653–663.
- De Clerck EE, Schouten JS, Berendschot TT, Beckers HJ, Schaper NC, Schram MT, Stehouwer CD & Webers CA (2017): Loss of temporal peripapillary retinal nerve fibers in prediabetes or type 2 diabetes without diabetic retinopathy: The Maastricht Study. *Invest Ophthalmol Vis Sci* **58**: 1017–1027.
- van Dijk HW, Verbraak FD, Kok PH et al. (2010): Decreased retinal ganglion cell layer thickness in patients with type 1 diabetes. *Invest Ophthalmol Vis Sci* **51**: 3660–3665.
- van Dijk HW, Verbraak FD, Kok PH et al. (2012): Early neurodegeneration in the retina of type 2 diabetic patients. *Invest Ophthalmol Vis Sci* **53**: 2715–2719.
- Friedenwald JS (1950): Diabetic retinopathy. *Am J Ophthalmol* **33**: 1187–1199.
- Frost-Larsen K, Larsen HW & Simonsen SE (1980): Oscillatory potential and nyctometry in insulin-dependent diabetics. *Acta Ophthalmol (Copenh)* **58**: 879–888.
- Garcia-Ramirez M, Hernandez C, Villarroel M et al. (2009): Interphotoreceptor retinoid-binding protein (IRBP) is downregulated at early stages of diabetic retinopathy. *Diabetologia* **52**: 2633–2641.
- Gardner TW, Abcouwer SF, Barber AJ & Jackson GR (2011): An integrated approach to diabetic retinopathy research. *Arch Ophthalmol* **129**: 230–235.
- Gastinger MJ, Singh RS & Barber AJ (2006): Loss of cholinergic and dopaminergic amacrine cells in streptozotocin-diabetic rat and Ins2Akita-diabetic mouse retinas. *Invest Ophthalmol Vis Sci* **47**: 3143–3150.
- Han Y, Adams AJ, Bearse MA Jr & Schneck ME (2004a): Multifocal electroretinogram and short-wavelength automated perimetry measures in diabetic eyes with little or no retinopathy. *Arch Ophthalmol* **122**: 1809–1815.
- Han Y, Bearse MA Jr, Schneck ME, Barez S, Jacobsen CH & Adams AJ (2004b): Multifocal electroretinogram delays predict sites of subsequent diabetic retinopathy. *Invest Ophthalmol Vis Sci* **45**: 948–954.
- von Hanno T, Lade AC, Mathiesen EB, Peto T, Njolstad I & Bertelsen G (2017): Macular thickness in healthy eyes of adults (N = 4508) and relation to sex, age and refraction: the Tromso Eye Study (2007–2008). *Acta Ophthalmol* **95**: 262–269.
- Hardy KJ, Lipton J, Scase MO, Foster DH & Scarpello JH (1992): Detection of colour vision abnormalities in uncomplicated type 1 diabetic patients with angiographically normal retinas. *Br J Ophthalmol* **76**: 461–464.
- Harrison WW, Bearse MA Jr, Ng JS, Jewell NP, Barez S, Burger D, Schneck ME & Adams AJ (2011): Multifocal electroretinograms predict onset of diabetic retinopathy in adult patients with diabetes. *Invest Ophthalmol Vis Sci* **52**: 772–777.
- Henson DB & North RV (1979): Dark adaptation in diabetes mellitus. *Br J Ophthalmol* **63**: 539–541.
- Kergoat H, Herard ME & Lemay M (2006): RGC sensitivity to mild systemic hypoxia. *Invest Ophthalmol Vis Sci* **47**: 5423–5427.
- Kern TS & Barber AJ (2008): Retinal ganglion cells in diabetes. *J Physiol* **586**: 4401–4408.
- Kim SY, Johnson MA, McLeod DS, Alexander T, Otsuji T, Steidl SM, Hansen BC & Luttj G (2004): Retinopathy in monkeys with spontaneous type 2 diabetes. *Invest Ophthalmol Vis Sci* **45**: 4543–4553.
- Kim NR, Lee ES, Seong GJ, Kang SY, Kim JH, Hong S & Kim CY (2011): Comparing the ganglion cell complex and retinal nerve fibre layer measurements by Fourier domain OCT to detect glaucoma in high myopia. *Br J Ophthalmol* **95**: 1115–1121.
- Kim MJ, Park KH, Yoo BW, Jeoung JW, Kim HC & Kim DM (2015): Comparison of macular GCIP and peripapillary RNFL deviation maps for detection of glaucomatous eye with localized RNFL defect. *Acta Ophthalmol* **93**: e22–e28.
- Klemp K, Sander B, Brockhoff PB, Vaag A, Lund-Andersen H & Larsen M (2005): The multifocal ERG in diabetic patients without retinopathy during euglycemic clamping. *Invest Ophthalmol Vis Sci* **46**: 2620–2626.
- Lam DS, Leung KS, Mohamed S et al. (2007): Regional variations in the relationship between macular thickness measurements and myopia. *Invest Ophthalmol Vis Sci* **48**: 376–382.
- Larsen MB, Henriksen JE, Grauslund J & Peto T (2017): Prevalence and risk factors for diabetic retinopathy in 17 152 patients from the island of Funen, Denmark. *Acta Ophthalmol* [Epub ahead of print].
- Lee K, Kwon YH, Garvin MK, Niemeijer M, Sonka M & Abramoff MD (2012): Distribution of damage to the entire retinal ganglion cell pathway: quantified using spectral-domain optical coherence tomography analysis in patients with glaucoma. *Arch Ophthalmol* **130**: 1118–1126.
- Lieth E, Barber AJ, Xu B, Dice C, Ratz MJ, Tanase D & Strother JM (1998): Glial reactivity and impaired glutamate metabolism in short-term experimental diabetic retinopathy. *Penn State Retina Research Group. Diabetes* **47**: 815–820.
- Martin PM, Roon P, Van Ells TK, Ganapathy V & Smith SB (2004): Death of retinal neurons in streptozotocin-induced diabetic mice. *Invest Ophthalmol Vis Sci* **45**: 3330–3336.
- Massin P, Erginay A, Haouchine B, Mehdi AB, Paques M & Gaudric A (2002): Retinal thickness in healthy and diabetic subjects measured using optical coherence tomography mapping software. *Eur J Ophthalmol* **12**: 102–108.
- McKinlay J & Marceau L (2000): US public health and the 21st century: diabetes mellitus. *Lancet* **356**: 757–761.
- Mizutani M, Gerhardinger C & Lorenzi M (1998): Muller cell changes in human diabetic retinopathy. *Diabetes* **47**: 445–449.
- Moreno PA, Konno B, Lima VC et al. (2011): Spectral-domain optical coherence tomography for early glaucoma assessment: analysis of macular ganglion cell complex versus peripapillary retinal nerve fiber layer. *Can J Ophthalmol* **46**: 543–547.
- Ng JS, Bearse MA Jr, Schneck ME, Barez S & Adams AJ (2008): Local diabetic retinopathy prediction by multifocal ERG delays over 3 years. *Invest Ophthalmol Vis Sci* **49**: 1622–1628.
- Ng DS, Gupta P, Tham YC, Peck CF, Wong TY, Ikram MK & Cheung CY (2015): Repeatability of perimacular ganglion cell complex analysis with spectral-domain optical coherence tomography. *J Ophthalmol* **2015**: 605940.
- Olafsdottir E, Andersson DK, Dedorsson I, Svardsudd K, Jansson SP & Stefansson E (2016): Early detection of type 2 diabetes mellitus and screening for retinopathy are associated with reduced prevalence and severity of retinopathy. *Acta Ophthalmol* **94**: 232–239.
- Ooto S, Hangai M, Sakamoto A et al. (2010): Three-dimensional profile of macular retinal thickness in normal Japanese eyes. *Invest Ophthalmol Vis Sci* **51**: 465–473.
- Ooto S, Hangai M, Tomidokoro A et al. (2011): Effects of age, sex, and axial length

- on the three-dimensional profile of normal macular layer structures. *Invest Ophthalmol Vis Sci* **52**: 8769–8779.
- Oshitari T, Hanawa K & Adachi-Usami E (2009): Changes of macular and RNFL thicknesses measured by Stratus OCT in patients with early stage diabetes. *Eye* **23**: 884–889.
- Ramlo-Halsted BA & Edelman SV (1999): The natural history of type 2 diabetes. Implications for clinical practice. *Prim Care* **26**: 771–789.
- Realini T, Lai MQ & Barber L (2004): Impact of diabetes on glaucoma screening using frequency-doubling perimetry. *Ophthalmology* **111**: 2133–2136.
- Rimayanti U, Latief MA, Arintawati P, Akita T, Tanaka J & Kiuchi Y (2014): Width of abnormal ganglion cell complex area determined using optical coherence tomography to predict glaucoma. *Jpn J Ophthalmol* **58**: 47–55.
- Rungger-Brandl E, Dosso AA & Leuenberger PM (2000): Glial reactivity, an early feature of diabetic retinopathy. *Invest Ophthalmol Vis Sci* **41**: 1971–1980.
- Sanchez-Tocino H, Alvarez-Vidal A, Maldonado MJ, Moreno-Montanes J & Garcia-Layana A (2002): Retinal thickness study with optical coherence tomography in patients with diabetes. *Invest Ophthalmol Vis Sci* **43**: 1588–1594.
- Schram MT, Sep SJ, van der Kallen CJ, Dagnelie PC, Koster A, Schaper N, Henry RM & Stehouwer CD (2014): The Maastricht Study: an extensive phenotyping study on determinants of type 2 diabetes, its complications and its comorbidities. *Eur J Epidemiol* **29**: 439–451.
- Simo R, Hernandez C & European Consortium for the Early Treatment of Diabetic Retinopathy (2014): Neurodegeneration in the diabetic eye: new insights and therapeutic perspectives. *Trends Endocrinol Metab* **25**: 23–33.
- Simonett JM, Scarinci F, Picconi F et al. (2017): Early microvascular retinal changes in optical coherence tomography angiography in patients with type 1 diabetes mellitus. *Acta Ophthalmol* [Epub ahead of print].
- Simonsen SE (1980): The value of the oscillatory potential in selecting juvenile diabetics at risk of developing proliferative retinopathy. *Acta Ophthalmol (Copenh)* **58**: 865–878.
- Sohn EH, van Dijk HW, Jiao C et al. (2016): Retinal neurodegeneration may precede microvascular changes characteristic of diabetic retinopathy in diabetes mellitus. *Proc Natl Acad Sci USA* **113**: E2655–E2664.
- Sokol S, Moskowitz A, Skarf B, Evans R, Molitch M & Senior B (1985): Contrast sensitivity in diabetics with and without background retinopathy. *Arch Ophthalmol* **103**: 51–54.
- Stricker S, Oberwahrenbrock T, Zimmermann H, Schroeter J, Endres M, Brandt AU & Paul F (2011): Temporal retinal nerve fiber loss in patients with spinocerebellar ataxia type 1. *PLoS ONE* **6**: e23024.
- Sugimoto M, Sasoh M, Ido M, Wakitani Y, Takahashi C & Uji Y (2005): Detection of early diabetic change with optical coherence tomography in type 2 diabetes mellitus patients without retinopathy. *Ophthalmologica* **219**: 379–385.
- Tang L, Zhang Y, Jiang Y, Willard L, Ortiz E, Wark L, Medeiros D & Lin D (2011): Dietary wolfberry ameliorates retinal structure abnormalities in db/db mice at the early stage of diabetes. *Exp Biol Med* **236**: 1051–1063.
- Vujosevic S, Pilotto E, Bottega E, Benetti E, Cavarzeran F & Midena E (2008): Retinal fixation impairment in diabetic macular edema. *Retina* **28**: 1443–1450.
- Wolter JR (1961): Diabetic retinopathy. *Am J Ophthalmol* **51**: 1123–1141.
- World Health Organization (2006): Definition and diagnosis of diabetes mellitus and intermediate hyperglycemia: report of a WHO/IDF consultation. Geneva, Switzerland.
- Zeng XX, Ng YK & Ling EA (2000): Neuronal and microglial response in the retina of streptozotocin-induced diabetic rats. *Vis Neurosci* **17**: 463–471.
- Zou H, Zhang X, Xu X & Yu S (2006): Quantitative *in vivo* retinal thickness measurement in chinese healthy subjects with retinal thickness analyzer. *Invest Ophthalmol Vis Sci* **47**: 341–347.

Received on April 2nd, 2017.  
Accepted on July 30th, 2017.

*Correspondence:*

Eline E.B. De Clerck, MD  
University Eye Clinic Maastricht  
PO Box 5800  
NL-6202 AZ Maastricht  
The Netherlands  
Tel: +31 6 36143602  
Fax: +31 43 3875343  
Email: eline.de.clerck@mumc.nl

The Regional Association of General Practitioners (Zorg in Ontwikkeling) is gratefully acknowledged for their contribution to The Maastricht Study, enabling the invitation of individuals with type 2 diabetes using information from their web-based electronic health record. This research was supported by grant 122047 from Fonds NutsOhra, The Netherlands. The Maastricht Study was supported by the European Regional Development Fund via OP-Zuid, the Province of Limburg, the Dutch Ministry of Economic Affairs (grant 31O.041), Stichting De Weijerhorst (Maastricht, The Netherlands), the Pearl String Initiative Diabetes (Amsterdam, The Netherlands), the Cardiovascular Center (CVC, Maastricht, The Netherlands), Cardiovascular Research Institute Maastricht (CARIM, Maastricht, The Netherlands), School for Public Health and Primary Care (CAPHRI, Maastricht, The Netherlands), School for Nutrition, Toxicology and Metabolism (NUTRIM, Maastricht, The Netherlands), Stichting Annadal (Maastricht, The Netherlands), Health Foundation Limburg (Maastricht, The Netherlands) and by unrestricted grants from Janssen-Cilag B.V. (Tilburg, The Netherlands), Novo Nordisk Farma B.V. (Alphen aan den Rijn, The Netherlands) and Sanofi-Aventis Netherlands B.V. (Gouda, The Netherlands). Equipment was supplied by Heidelberg Engineering and the University Eye Clinic Maastricht.