

Structural damage and inflammation on radiographs or magnetic resonance imaging are associated with cortical interruptions on high-resolution peripheral quantitative computed tomography

Citation for published version (APA):

Scharmga, A., Geusens, P. P. M. M., Peters, M., van den Bergh, J. P. W., Loeffen, D., Schoonbrood, T., van Rietbergen, B., Vosse, D., Weijers, R. A. M., & van Tubergen, A. (2018). Structural damage and inflammation on radiographs or magnetic resonance imaging are associated with cortical interruptions on high-resolution peripheral quantitative computed tomography: a study in finger joints of patients with rheumatoid arthritis and healthy subjects. *Scandinavian Journal of Rheumatology*, 47(6), 431-439.
<https://doi.org/10.1080/03009742.2018.1424234>

DOI:

[10.1080/03009742.2018.1424234](https://doi.org/10.1080/03009742.2018.1424234)

Document status and date:

Published: 02/11/2018

Document Version:

Publisher's PDF, also known as Version of Record (includes final page, issue and volume numbers)

Please check the document version of this publication:

- A submitted manuscript is the version of the article upon submission and before peer-review. There can be important differences between the submitted version and the official published version of record. People interested in the research are advised to contact the author for the final version of the publication, or visit the DOI to the publisher's website.
- The final author version and the galley proof are versions of the publication after peer review.
- The final published version features the final layout of the paper including the volume, issue and page numbers.

[Link to publication](#)

General rights

Copyright and moral rights for the publications made accessible in the public portal are retained by the authors and/or other copyright owners and it is a condition of accessing publications that users recognise and abide by the legal requirements associated with these rights.

- Users may download and print one copy of any publication from the public portal for the purpose of private study or research.
- You may not further distribute the material or use it for any profit-making activity or commercial gain
- You may freely distribute the URL identifying the publication in the public portal.

If the publication is distributed under the terms of Article 25fa of the Dutch Copyright Act, indicated by the "Taverne" license above, please follow below link for the End User Agreement:

www.tue.nl/taverne

Take down policy

If you believe that this document breaches copyright please contact us at:

openaccess@tue.nl

providing details and we will investigate your claim.



Structural damage and inflammation on radiographs or magnetic resonance imaging are associated with cortical interruptions on high-resolution peripheral quantitative computed tomography: a study in finger joints of patients with rheumatoid arthritis and healthy subjects

A Scharmga, P Geusens, M Peters, JP van den Bergh, D Loeffen, T Schoonbrood, B van Rietbergen, D Vosse, R Weijers & A van Tubergen

To cite this article: A Scharmga, P Geusens, M Peters, JP van den Bergh, D Loeffen, T Schoonbrood, B van Rietbergen, D Vosse, R Weijers & A van Tubergen (2018) Structural damage and inflammation on radiographs or magnetic resonance imaging are associated with cortical interruptions on high-resolution peripheral quantitative computed tomography: a study in finger joints of patients with rheumatoid arthritis and healthy subjects, *Scandinavian Journal of Rheumatology*, 47:6, 431-439, DOI: [10.1080/03009742.2018.1424234](https://doi.org/10.1080/03009742.2018.1424234)

To link to this article: <https://doi.org/10.1080/03009742.2018.1424234>



© 2018 The Author(s). Published by Informa UK Limited, trading as Taylor & Francis Group.



Published online: 20 Feb 2018.



Submit your article to this journal [↗](#)



Article views: 403



View Crossmark data [↗](#)

Structural damage and inflammation on radiographs or magnetic resonance imaging are associated with cortical interruptions on high-resolution peripheral quantitative computed tomography: a study in finger joints of patients with rheumatoid arthritis and healthy subjects

A Scharmga^{1,2,3}, P Geusens^{1,3,4}, M Peters^{1,2,3}, JP van den Bergh^{1,2,4,5}, D Loeffen⁶, T Schoonbrood¹, B van Rietbergen^{7,8}, D Vosse¹, R Weijers⁶, A van Tubergen^{1,3}

¹Department of Medicine, Division of Rheumatology, Maastricht University Medical Center, Maastricht, The Netherlands

²NUTRIM School of Nutrition and Translational Research in Metabolism, Maastricht University, Maastricht, The Netherlands

³CAPHRI Care and Public Health Research Institute, Maastricht University, Maastricht, The Netherlands

⁴Department of Internal Medicine, Viecuri Medical Center, Venlo, The Netherlands

⁵Faculty of Medicine and Life Sciences, Hasselt University, Hasselt, Belgium

⁶Department of Radiology, Maastricht University Medical Center, Maastricht, The Netherlands

⁷Department of Biomedical Engineering, Eindhoven University of Technology, Eindhoven, The Netherlands

⁸Department of Orthopaedic Surgery, Maastricht University Medical Center, Maastricht, The Netherlands

Objectives: To study the relationship between structural damage and inflammatory features on magnetic resonance imaging (MRI) or radiography and other risk factors [anti-citrullinated protein antibody (ACPA) and/or rheumatoid factor (RF) seropositivity, hand dominance, disease duration] and the presence or number of cortical interruptions in finger joints on high-resolution peripheral quantitative computed tomography (HR-pQCT).

Method: Finger joints of 38 healthy subjects and 39 patients with rheumatoid arthritis (RA) were examined through radiographs, MRI, and HR-pQCT. Radiographs were scored according to the Sharp/van der Heijde (SvH) method; MRI for the presence of cortical interruptions, bone marrow oedema (BMO), and synovitis; and HR-pQCT images for cortical interruptions. Descriptive statistics were calculated and associations examined using generalized estimating equations.

Results: Cortical interruptions were found in healthy subjects and patients with RA on HR-pQCT (mean \pm sd 0.33 ± 0.63 vs 0.38 ± 0.64 per joint quadrant, respectively, $p < 0.01$). Structural damage on MRI (cortical interruptions) or radiographs (SvH ≥ 1) was associated with the presence of cortical interruptions on HR-pQCT [odds ratio (OR) 12.4, 95% confidence interval (CI) 7.5–21.4, $p < 0.01$ and OR 4.8, 95% CI 1.9–11.7, respectively, $p < 0.01$]. The presence of BMO or synovitis was associated with more cortical interruptions on HR-pQCT (β 0.47, 95% CI 0.4–0.6, $p < 0.01$ and β 1.9, 95% CI 0.6–3.1, $p < 0.01$). In patients with RA, ACPA, and/or RF seropositivity, hand dominance and disease duration were not associated with more cortical interruptions on HR-pQCT.

Conclusion: Structural damage and inflammatory features on MRI and radiographs are associated with cortical interruptions on HR-pQCT. No association between other risk factors and cortical interruptions was demonstrated.

Rheumatoid arthritis (RA) is an inflammatory autoimmune disease characterized by cortical interruptions of the bone. The presence, size, and number of those cortical interruptions on radiographs are risk factors for poor long-term disease outcome (1, 2). Sensitive and reproducible imaging methods are therefore essential for the diagnosis,

management, and monitoring of RA. Radiographs are used as the gold standard to assess structural damage in standard clinical care. Markers of inflammation such as bone marrow oedema (BMO) and synovitis can be evaluated by magnetic resonance imaging (MRI). The presence of BMO on MRI has been associated with progression of damage on radiographs (3, 4). High-resolution peripheral quantitative computed tomography (HR-pQCT) is another imaging technique used to assess cortical and trabecular bone structure in greater detail (5, 6). Studies to validate the use of HR-pQCT in imaging cortical interruptions in finger joints have been initiated. Comparative studies of HR-pQCT, MRI, and

Astrid van Tubergen, Department of Medicine, Division of Rheumatology, Maastricht University Medical Center, PO Box 5800, Maastricht, AZ NL-6202, The Netherlands.
E-mail: a.van.tubergen@mumc.nl

Accepted 3 January 2018

© 2018 The Author(s). Published by Informa UK Limited, trading as Taylor & Francis Group.

This is an Open Access article distributed under the terms of the Creative Commons Attribution-NonCommercial-NoDerivatives License (<http://creativecommons.org/licenses/by-nc-nd/4.0/>), which permits non-commercial re-use, distribution, and reproduction in any medium, provided the original work is properly cited, and is not altered, transformed, or built upon in any way.

DOI: <https://doi.org/10.1080/03009742.2018.1424234>

www.scandjrheumatol.dk

radiography of finger joints showed that HR-pQCT is more sensitive than MRI and radiographs in detecting cortical interruptions (5, 7, 8). However, these studies predominantly focused on established pathological interruptions, i.e. erosions. Studies with MRI and HR-pQCT further showed that inflammatory changes and cortical interruptions can also be found in finger joints of healthy subjects (5, 9). We demonstrated in an earlier study that cortical interruptions in finger joints detected on HR-pQCT have a heterogeneous spectrum; some of them had adjacent trabecular distortion suggestive of an erosion, and some may represent physiological vascular channels (10). It is hypothesized that vascular channels may serve as a starting point for pathological cortical interruptions as they provide direct entry for osteoclast-mediated joint destruction (11–13). The osteoclasts are activated by inflammation; however, in anti-citrullinated protein antibody (ACPA)-positive patients with RA, bone loss was also observed in the absence of inflammation (1, 14, 15). Besides ACPA seropositivity, other factors such as hand dominance and disease duration have also been associated with the presence and progression of structural damage in hand joints (16–18). Currently, studies evaluating the relationship between structural damage and/or inflammatory features on either MRI or radiography with the presence or number of cortical interruptions in finger joints on HR-pQCT are lacking. Furthermore, it is unknown whether several other risk factors for structural damage, such as ACPA and rheumatoid factor (RF) immunoglobulin M seropositivity, hand dominance, and disease duration, are also associated with more cortical interruptions on HR-pQCT.

The aims of this study were to validate further the use of HR-pQCT by investigating the association between (i) structural damage on either MRI or radiography and the presence of cortical interruptions on HR-pQCT images of finger joints in healthy subjects and patients with RA; (ii) markers of inflammation on MRI (BMO and synovitis) and the number of cortical interruptions on HR-pQCT in healthy subjects and patients with RA; and (iii) ACPA and RF seropositivity, hand dominance, or disease duration and the number of cortical interruptions on HR-pQCT in patients with RA.

Method

Subjects

For this cross-sectional study, we used data from the MOSA-Hand cohort, which consists of 38 female healthy subjects and 41 female patients diagnosed with RA. All subjects were recruited at the Maastricht University Medical Center, the Netherlands. All patients with RA fulfilled the 2010 American College of Rheumatology (ACR)/European League Against Rheumatism (EULAR) classification criteria for RA (19). Exclusion criteria for patients with RA were: primary hyperthyroidism, primary hyperparathyroidism, chronic kidney disease (estimated glomerular filtration rate < 30 mL/min), sarcoidosis, and other rheumatic diseases involving the joints (such as osteoarthritis). Information on

medication use, ACPA, and RF positivity was retrieved from the patients' medical files. Healthy subjects, matched per decade, had no history of rheumatic disease or metabolic bone disease, and none reported use of osteoporotic medication.

All subjects signed informed consent. Ethical approval was obtained from the ethics board of the academic hospital Maastricht/Maastricht University, the Netherlands. The study was registered with the Netherlands Trial Register (number NTR4523). Procedures followed were in accordance with the ethical standards of the responsible committee on human experimentation and with the Declaration of Helsinki.

HR-pQCT image acquisition and scoring

In accordance with to the HR-pQCT imaging protocol proposed by the Study group for xtrEme Computed Tomography in Rheumatoid Arthritis (SPECTRA) (20), the second and third metacarpophalangeal (MCP) and proximal interphalangeal (PIP) joints were scanned with HR-pQCT (XtremeCT1; Scanco Medical, Brüttisellen, Switzerland). Each hand was separately scanned using the standard carbon forearm cast provided by the manufacturer. In healthy subjects only the dominant hand was scanned and in patients with RA both hands were scanned.

One experienced reader (AS) scored all HR-pQCT images, blinded for group, demographic and clinical data, according to a visual scoring algorithm for HR-pQCT as described elsewhere (A Scharmga et al, unpublished observations). A subset of HR-pQCT images of 30 subjects was scored twice by two readers (MP and AS), again blinded for group, demographic and clinical data. The intrareader (reader AS) intraclass correlation coefficient (ICC) was 0.69 [95% confidence interval (CI) 0.65–0.73] per quadrant and the interreader ICC was 0.56 (95% CI 0.49–0.62) per quadrant (A Scharmga et al, unpublished observations). The scores from reader AS were used for the present analyses.

In brief, first, images were assessed for image quality according to Pialat et al (21). Secondly, each joint was divided into its proximal and distal bone ends (i.e. metacarpal head or phalangeal base in the case of an MCP joint, or distal end phalanx and phalangeal base in the case of a PIP joint). When more than 50% of the joint surface of the cortical bone was destroyed, the bone end was considered 'totally destroyed' and the bone end was excluded from further examination. Thirdly, each bone end was further divided into four quadrants (palmar, ulnar, dorsal, and radial). Fourthly, a cortical interruption was scored when it fulfilled one of the following criteria: (i) an interruption in at least one slice in one plane and also in two consecutive slices in another plane (i.e. $1 \times \geq 2$ or $\geq 2 \times 1$ slices); and (ii) an interruption in more than one consecutive slice in one plane and in more than one slice in another plane (e.g. $\geq 2 \times \geq 2$ slices). Fifthly, the adjacent

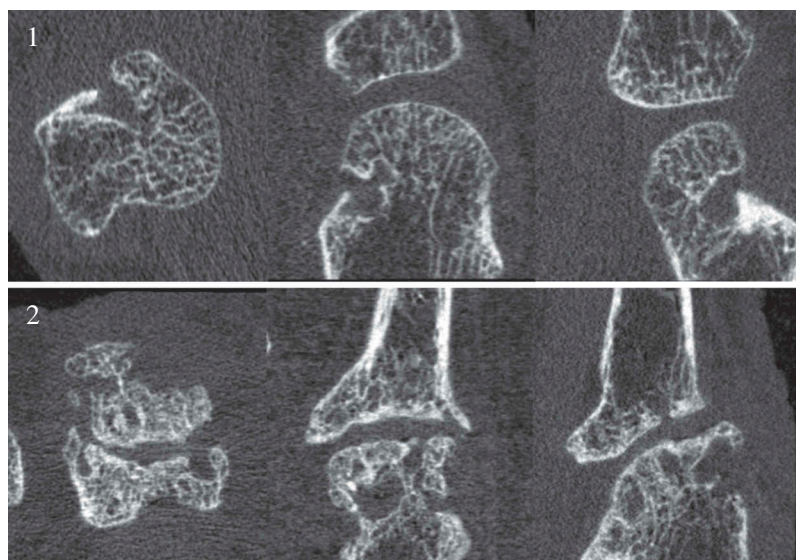


Figure 1. Panel 1: Example of a cortical interruption in axial, coronal, and sagittal view on the radial side of a metacarpal head on high-resolution peripheral quantitative computed tomography (HR-pQCT). Panel 2: Example of an axial, coronal, and sagittal HR-pQCT image of a totally destroyed bone end excluded from further examination.

trabecular structure was assessed for distortion. In Figure 1, panel 1, an example is shown of a cortical interruption in the metacarpal head on HR-pQCT. In panel 2, an example is shown of a totally destroyed bone end which was excluded from further examination.

MRI acquisition and scoring

Second and third MCP and PIP joints of both hands of patients with RA and healthy subjects were examined using a 3.0 T Achieva Philips MRI device (Eindhoven, The Netherlands). During the examination, the hand was fixed inside a dedicated wrist coil and the space around the hand was filled with rubber to reduce motion artefacts. Images were acquired of both hands using axial T1-weighted, axial fat-suppressed T2-weighted, and sagittal three-dimensional water-selective T1-weighted fat-suppressed sequences. Additional images were acquired after intravenous gadolinium administration (Gadovist®, Bayer AG, Berlin, Germany, 1.0 mmol/mL solution for injection) using axial and coronal fat-suppressed T1-weighted images.

The MRI images were independently scored by two radiologists (DL and RW), blinded for clinical data, structural damage (the presence of cortical interruptions), and markers of inflammation (the presence of BMO and synovitis). The presence of a cortical interruption and BMO was evaluated per joint quadrant. Synovitis was evaluated per joint. In case of a discrepancy, the case was reviewed and discussed between the readers until consensus was reached.

Conventional radiography acquisition and scoring

Posterior–anterior radiographs of both hands were taken from all subjects according to a standard clinical protocol. Two experienced and trained rheumatologists (DV and TS) independently scored the radiographs of the

hands to assess structural bone damage according to the Sharp/van der Heijde (SvH) method (22). Both readers were blinded for group, demographic and clinical data. Mean scores of the two readers were calculated and used for the analyses. For the present analyses, only the SvH scores on the second and third MCP and PIP joints were taken into account. Radiographic damage was considered present when the SvH score was ≥ 1 .

Statistics

Descriptive statistics for baseline characteristics and the scores on HR-pQCT, MRI, and radiographs were calculated. Differences between healthy subjects and patients with RA were calculated using Mann–Whitney U-tests or chi-squared tests, as appropriate. Stratified analyses were carried out in patients with RA and analysed by the Mann–Whitney U-test (ACPA- and/or RF-positive versus -negative patients, < 2 years' versus > 2 years' disease duration) or Wilcoxon signed rank test (dominant versus non-dominant hand).

Possible associations between structural damage, markers of inflammation, and other risk factors (ACPA and/or RF positivity, hand dominance, and disease duration) and the presence or number of cortical interruptions on HR-pQCT images were tested using generalized estimating equations (GEEs). An exchangeable working correlation structure was assumed to adjust for within-subject correlation. For the presence of structural damage, a binary model was used, providing an odds ratio (OR). For inflammatory features and other risk factors, a linear model was used, providing a beta (β) value. All GEE analyses were performed on the quadrant level, except for synovitis on MRI, which was performed on the joint level.

According to the visual scoring algorithm, totally destroyed bone ends (when more than 50% of the bone end is totally destroyed) were excluded from the evaluation on the presence of cortical interruptions because of the indefinable boundaries, which would lead to

inaccurate measures and more discrepancies between readers (see, for example, Figure 1, panel 2). Instead, we assigned a (conservative) count of 'one' cortical interruption for each quadrant, and thus in total four cortical interruptions for each totally destroyed bone end. Count 'one' was chosen based on the median score of the total number of cortical interruptions per affected quadrant in patients with RA (median 1, range 1–4 per quadrant).

Statistical analyses were performed with SPSS Statistics for Windows version 23.0 (IBM Corp., Armonk, NY, USA).

Results

Of the 38 healthy subjects and 41 patients with RA who were recruited, two patients with RA did not have an HR-pQCT scan available and were excluded from further analyses. In one subject (a patient with RA), HR-pQCT images of four PIP joints were not scanned owing to intolerance to long immobilization during scanning, but the remaining joints were included in the analyses. Table 1 shows the characteristics of the study population. Patients with RA were numerically, but not significantly older than the healthy subjects ($p = 0.08$). An example of a normal MCP joint and an example of a totally destroyed bone end visualized on the corresponding radiograph, HR-pQCT images, and MRI image are shown in Figure 2.

HR-pQCT

Table 2 shows the results of the HR-pQCT visual scoring method for healthy subjects and patients with RA. In total, 308 joints (2464 quadrants) were analysed in patients with RA, and 152 joints (1216 quadrants) in healthy subjects. Totally destroyed bone ends were only seen in patients with

RA ($n = 9$) in 76 quadrants (3% of the quadrants analysed in patients with RA). The mean number of cortical interruptions per quadrant was significantly higher in patients with RA than in healthy subjects ($p < 0.01$). A higher proportion of cortical interruptions with adjacent trabecular distortion was also seen in patients with RA than in healthy subjects (25% versus 10%, $p < 0.01$).

Comparative stratified analyses for ACPA- and/or RF-positive versus -negative patients with RA did not show significant differences in the mean number of cortical interruptions and adjacent trabecular distortion. The results from those patients who were both ACPA and RF positive ($n = 21$) versus negative patients were also not significantly different (data not shown).

In the dominant hand of patients with RA, cortical interruptions both with and without adjacent trabecular distortion were more frequently found in the dominant hand than in the non-dominant hand ($p < 0.01$ and $p < 0.05$, respectively). Patients with > 2 years' versus < 2 years' disease duration had a significantly higher mean number of cortical interruptions per quadrant and a higher proportion of cortical interruptions with adjacent trabecular distortion (both $p < 0.01$).

MRI

Table 3 shows the results of MRI scoring. In total, 75 baseline MRI scans of the 77 subjects who were imaged by HR-pQCT were available and scored (37 healthy subjects and 38 patients with RA). In one subject, MRI images of four PIP joints were missing because of technical issues. As a result of motion artefacts, 12 joints were not evaluable for BMO and 14 joints were not evaluable for cortical interruptions and synovitis. A statistically significant higher proportion of quadrants with structural damage (cortical interruptions) and inflammatory markers (BMO and synovitis) was found in

Table 1. Characteristics of the study population.

	Healthy subjects (n = 38)	Patients with RA (n = 39)
Age (years)	51.2 ± 10.3	54.8 ± 7.0
Disease duration (months)	N/A	131.7 ± 116.6
ACPA and/or RF positive	N/A	30 (77)
ACPA positive	N/A	24 (59)
RF positive	N/A	27 (66)
ACPA and RF positive	N/A	21 (54)
DMARD use	N/A	34 (87)
Biological use	N/A	20 (51)
DMARD and biological use	N/A	15 (38)
Osteoporosis treatment (alendronic acid)	0	1 (3)
Prednisone (> 5 mg/day)	0	4 (10)

Data are shown as mean ± sd or absolute number (%).

RA, rheumatoid arthritis; ACPA, anti-citrullinated protein antibody; RF, rheumatoid factor; DMARD, disease-modifying anti-rheumatic drug; N/A, not applicable.

In two patients, ACPA values were missing.

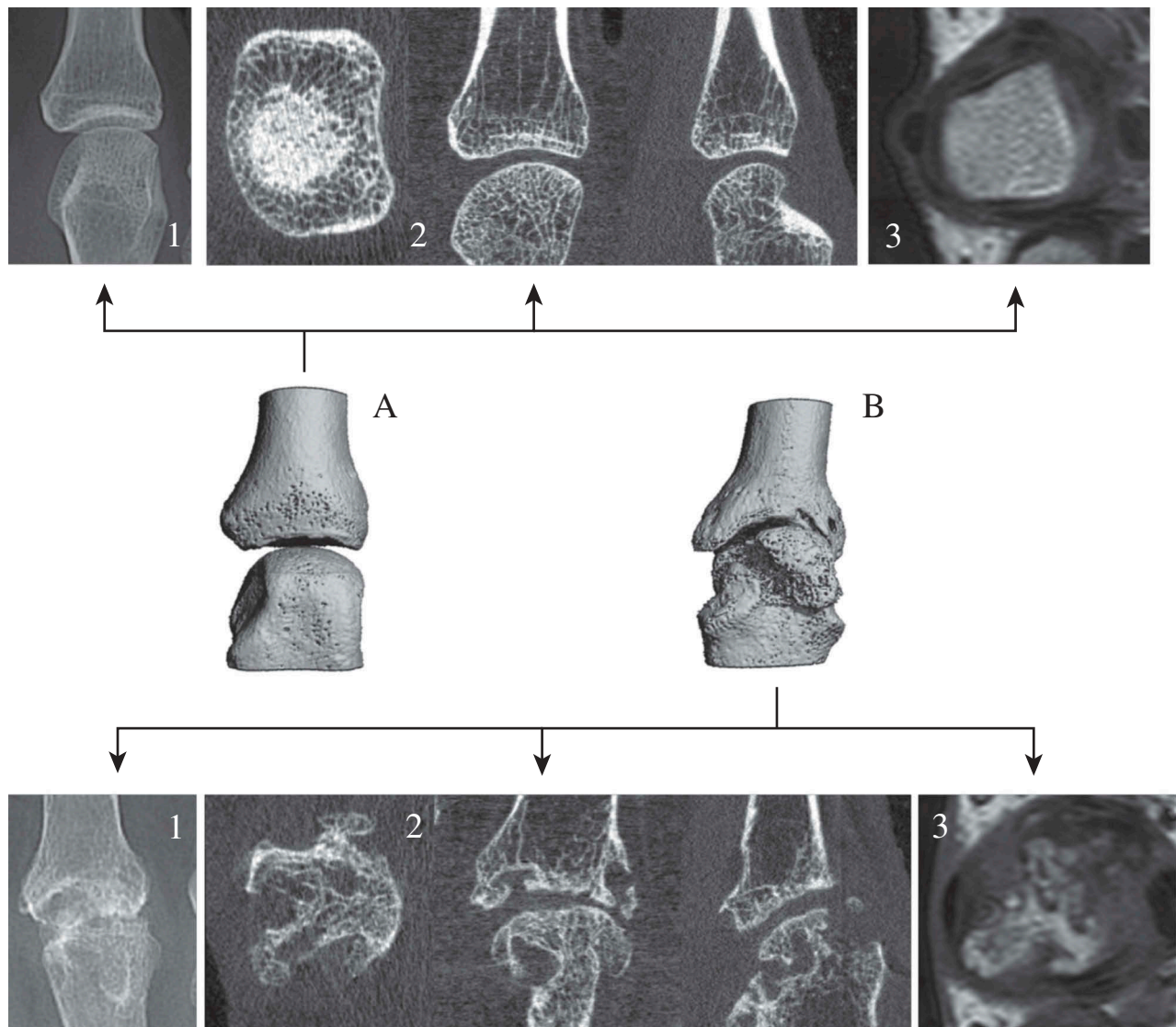


Figure 2. Two examples of metacarpophalangeal (MCP) joints. Example A: An MCP joint in a healthy subject with corresponding radiograph; axial, coronal, and sagittal high-resolution peripheral quantitative computed tomography (HR-pQCT) images; and magnetic resonance imaging (MRI) image. Example B: A totally destroyed joint in a patient with rheumatoid arthritis with corresponding radiograph; axial, coronal, and sagittal HR-pQCT images; and MRI image. Same subject as in Figure 1, panel 2.

patients with RA than in healthy subjects (all $p < 0.01$) (Table 3).

In ACPA- and/or RF-positive patients, the proportion of quadrants with BMO was significantly higher than in seronegative patients ($p < 0.01$) (Table 3). Comparable results were found for patients who were both RF and ACPA positive versus negative ($p < 0.01$, data not shown). In the dominant hand of patients with RA, the proportion of quadrants with BMO was significantly higher than in the non-dominant hand ($p < 0.01$) (Table 3). Furthermore, in patients with > 2 years' disease duration, the proportion of quadrants with either cortical interruptions or BMO, and joints with synovitis was higher than in

patients with < 2 years' disease duration (all $p < 0.05$) (Table 3).

Radiographs

In total, 75 baseline radiographs of the 77 subjects with an HR-pQCT scan were available and scored (36 healthy subjects and 39 patients with RA). The mean \pm sd total SvH score based on two readers was 1.1 ± 1.8 (range 0–10) for healthy subjects and 9.1 ± 17.3 (range 0–87.5) for patients with RA. Five patients with RA showed the presence of radiographic damage (SvH ≥ 1) in total 10 joints specifically examined in this study (joint examined

Table 2. Results of high-resolution peripheral quantitative computed tomography (HR-pQCT) scoring using the visual scoring algorithm.

	Healthy subjects (n = 38)	Patients with RA (n = 39)	Patients with RA					
			ACPA and/or RF positive (n = 30)	ACPA and RF negative (n = 9)	Dominant hand (n = 39)	Non-dominant hand (n = 39)	< 2 years' disease duration (n = 10)	> 2 years' disease duration (n = 29)
No. of evaluable quadrants	1142 (94)	2314 (94)						
No. of interruptions	375	883	681	202	465	418	202	681
No. of interruptions per evaluable quadrant	0.33 ± 0.63	0.38 ± 0.64	0.38 ± 0.64	0.38 ± 0.65	0.40 ± 0.65	0.36 ± 0.64	0.32 ± 0.62	0.41 ± 0.65
No. of interruptions with adjacent trabecular distortion	39 (10)	224 (25)	176 (26)	48 (24)	147 (32)	77 (18)	23 (11)	201 (30)

Data are shown as number (%), number, or mean ± sd.

RA, rheumatoid arthritis; ACPA, anti-citrullinated protein antibody; RF, rheumatoid factor. In two patients, ACPA values were missing.

Table 3. Results of magnetic resonance imaging (MRI) scoring.

	Healthy subjects (n = 37)	Patients with RA (n = 38)	Patients with RA					
			ACPA and/or RF positive (n = 30)	ACPA and RF negative (n = 8)	Dominant hand (n = 38)	Non-dominant hand (n = 38)	< 2 years' disease duration (n = 10)	> 2 years' disease duration (n = 29)
No. of quadrants evaluable for cortical interruptions*	1152	2320	1736	584	1200	1120	544	1776
No. of quadrants with cortical interruptions	29 (2.5)	181 (7.8)	130 (7.0)	51 (9.0)	110 (9.0)	71 (6.0)	21 (4.0)	160 (9.0)
No. of quadrants evaluable for BMO*	1152	2300	1720	580	1196	1104	544	1756
No. of quadrants with BMO	2 (1.0)	62 (2.7)	59 (3.0)	3 (0.01)	47 (4.0)	15 (1.4)	1 (0.01)	61 (3.0)
No. of joints evaluable for synovitis*	148	296	227	69	148	148	69	227
No. of joints with synovitis	3 (2.0)	32 (10.8)	25 (11)	7 (10)	21 (14)	11 (7.0)	3 (4.0)	29 (13)

Data are shown as absolute number or number (%).

RA, rheumatoid arthritis; ACPA, anti-citrullinated protein antibody; RF, rheumatoid factor; BMO, bone marrow oedema.

*Four proximal interphalangeal joints were missing in one patient with RA. Owing to motion artefacts, 12 joints were not evaluable for BMO and 14 joints were not evaluable for synovitis and BMO. In two patients, ACPA values were missing.

MCP 2 and 3, and PIP 2 and 3, bilaterally). In the healthy subjects, no radiographic damage was observed in these joints.

Association between structural damage and presence of cortical interruptions on HR-pQCT

Univariable GEE analysis showed a significant association between structural damage (the presence of a cortical interruption) per quadrant on MRI and the presence of a cortical interruption per quadrant on HR-pQCT (total population: OR 12.4, 95% CI 7.5–21.4, $p < 0.01$; patients with RA: OR 11.1, 95% CI 6.3–19.5, $p < 0.01$). Radiographic damage (SvH ≥ 1 yes/no) was also associated with the presence of cortical interruptions on HR-pQCT (total population: OR 4.8, 95% CI 1.9–11.7, $p < 0.01$; patients with RA: OR 4.5, 95% CI 1.8–11.7, $p < 0.01$).

Association between markers of inflammation and number of cortical interruptions on HR-pQCT

The presence of BMO was significantly associated with more cortical interruptions per quadrant on HR-pQCT (total population: β 0.5, 95% CI 0.5–0.6, $p < 0.01$; patients with RA: β 0.5, 95% CI 0.4–0.6, $p < 0.01$). Synovitis of the joint was also significantly associated with more cortical interruptions on HR-pQCT (total population: β 1.9, 95% CI 0.6–3.1, $p < 0.01$, patients with RA: β 2.0, 95% CI 0.7–3.4, $p < 0.01$).

Association between other risk factors and number of cortical interruptions on HR-pQCT

In GEE analysis in patients with RA, the presence of ACPA and/or RF was not associated with more cortical interruptions per quadrant on HR-pQCT (β 0.0, 95% CI –0.1 to 0.1, $p = 0.94$). Hand dominance and disease duration did not show a significant association with the number of cortical interruptions per quadrant on HR-pQCT (β 0.0, 95% CI –0.0 to 0.1, $p = 0.21$ and β 0.1, 95% CI 0.0 to 0.2, $p = 0.06$ respectively).

Discussion

This article aimed to study associations between structural damage, markers of inflammation, and other risk factors on the presence and number of cortical interruptions on HR-pQCT. Cortical interruptions, with or without adjacent trabecular distortion, were seen in both healthy subjects and patients with RA on HR-pQCT, but more frequently in patients with RA. Structural damage on MRI or radiographs was significantly associated with the presence of cortical interruptions on HR-pQCT. When BMO and synovitis were present, significantly more cortical interruptions were found on HR-pQCT. In patients with RA, ACPA and/or RF

seropositivity, hand dominance and disease duration were not associated with the number of cortical interruptions on HR-pQCT. Previous studies showed that the presence of BMO on MRI is associated with cortical interruptions and progression of structural damage on radiographs (3, 4, 23). Also, BMO and synovitis in the joints in a healthy, symptom-free, study population have been observed on MRI (57.5% and 48.2%, respectively) (9). In our study, we also found BMO in both patients with RA and healthy subjects. When BMO was present, more cortical interruptions on HR-pQCT were found, both in the total population, including healthy subjects, and in patients with RA.

A clear relationship between the presence of ACPA and/or RF and more radiographic damage has been reported (24). Using quantitative analyses, Kleyer et al showed significant bone loss in finger joints on HR-pQCT before the clinical onset of RA in ACPA-positive subjects without signs of arthritis compared with ACPA-negative subjects (15). In the present study, we were unable to demonstrate more cortical interruptions on HR-pQCT in patients who are ACPA and/or RF positive. This could be explained by lack of statistical power due to a low number of patients in the ACPA- and RF-negative group ($n = 9$), but also by the fact that all patients included in this study received treatment, of which more than 50% comprised a biological. In a study using HR-pQCT, repair of large cortical interruptions detected in patients with RA after treatment with tumour necrosis factor inhibitors has been demonstrated (25).

To date, only limited research on structural damage between the dominant and non-dominant hands has been performed, showing more structural damage in the dominant hand (16, 18). In a crude comparative analysis, we found significantly more cortical interruptions per quadrant on HR-pQCT in the dominant hand versus the non-dominant hand. Because the presence of structural damage is associated with more damage in the same subject (26), we corrected for this within-subject correlation using GEE analyses, after which the association could no longer be demonstrated. The same was observed with disease duration, which showed a significant difference in the crude comparative analyses, but no association in the GEE analyses.

The strengths of the present study are that it was performed both in patients with RA and in healthy subjects, and we were able to compare findings on three different imaging modalities in the same patient.

An important limitation is that the visual scoring method for HR-pQCT takes into account all cortical interruptions and does not distinguish between physiological vascular channels and pathological erosions, which may be the reason why many cortical interruptions were found in healthy subjects. In a previous study, we demonstrated that defining a cortical interruption as a vascular channel on HR-pQCT is challenging, compared to the gold standard histology (27). We are not aware of studies that compared cortical interruptions defined as erosions on HR-pQCT with histology, but can imagine that this

would also be difficult. It is hypothesized that vascular channels could be the starting point for pathological cortical interruptions (11–13). Werner et al showed the presence of cortical microchannels in a specific region on the joint; the bare area, an area considered prone to development of cortical interruptions. Patients with RA showed more cortical microchannels at a younger age, compared with healthy individuals at a higher age (28). Longitudinal studies are needed to explore the role of these physiological cortical interruptions and/or cortical microchannels in the development of pathological cortical interruptions. Another limitation is the moderate interreader reliability of the visual scoring algorithm, which is probably due to the inclusion of small cortical interruptions by the algorithm (A Scharmga et al, unpublished observations). However, wide ranges in reliability (from moderate to almost perfect, 0.47–1.00) are also observed with other imaging techniques, such as conventional radiographs, despite being scored by experienced readers (29). A third limitation is that the images were not fused to each other; however, we wanted to use independent observations on each imaging modality. Finally, no C-reactive protein levels or erythrocyte sedimentation rates were checked in healthy subjects.

Conclusion

In conclusion, structural damage and inflammatory features on radiographs and MRI are associated with more cortical interruptions on HR-pQCT. No association between other risk factors and more cortical interruptions could be demonstrated.

Acknowledgements

This study was funded by an unrestricted grant from Pfizer and the Weijerhorst Foundation.

Disclosure statement

No potential conflict of interest was reported by the authors.

References

1. Gravallesse EM, Walsh NC. Rheumatoid arthritis: repair of erosion in RA—shifting the balance to formation. *Nat Rev Rheumatol* 2011;7:626–8.
2. Lillegraven S, van der Heijde D, Uhlig T, Kvien TK, Haavardsholm EA. What is the clinical relevance of erosions and joint space narrowing in RA? *Nat Rev Rheumatol* 2012;8:117–20.
3. Gandjbakhch F, Foltz V, Mallet A, Bourgeois P, Fautrel B. Bone marrow oedema predicts structural progression in a 1-year follow-up of 85 patients with RA in remission or with low disease activity with low-field MRI. *Ann Rheum Dis* 2011;70:2159–62.
4. Hetland ML, Ejlberg B, Hørslev-Petersen K, Jacobsen S, Vestergaard A, Jurik AG, et al. MRI bone oedema is the strongest predictor of subsequent radiographic progression in early rheumatoid arthritis. Results from a 2-year randomised controlled trial (CIMESTRA). *Ann Rheum Dis* 2009;68:384–90.
5. Stach CM, Bäuerle M, Englbrecht M, Kronke G, Engelke K, Manger B, et al. Periarticular bone structure in rheumatoid arthritis patients and healthy individuals assessed by high-resolution computed tomography. *Arthritis Rheum* 2010;62:330–9.
6. Barnabe C, Toepfer D, Marotte H, Hauge E-M, Scharmga A, Kocijan R, et al. Definition for rheumatoid arthritis erosions imaged with high resolution peripheral quantitative computed tomography and interreader reliability for detection and measurement. *J Rheumatol* 2016;43:1935–40.
7. Regensburger A, Rech J, Englbrecht M, Finzel S, Kraus S, Hecht K, et al. A comparative analysis of magnetic resonance imaging and high-resolution peripheral quantitative computed tomography of the hand for the detection of erosion repair in rheumatoid arthritis. *Rheumatology (Oxford)* 2015;54:1573–81.
8. Lee CH, Srikkum W, Burghardt AJ, Virayavanich W, Imboden JB, Link TM, et al. Correlation of structural abnormalities of the wrist and metacarpophalangeal joints evaluated by high-resolution peripheral quantitative computed tomography, 3 Tesla magnetic resonance imaging and conventional radiographs in rheumatoid arthritis. *Int J Rheum Dis* 2015;18:628–39.
9. Mangnus L, van Steenbergen HW, Reijniers M, van der Helm-van Mil AH. Magnetic resonance imaging-detected features of inflammation and erosions in symptom-free persons from the general population. *Arthritis Rheumatol* 2016;68:2593–602.
10. Scharmga A, Peters M, van Tubergen A, van den Bergh J, Barnabe C, Finzel S, et al. Heterogeneity of cortical breaks in hand joints of patients with rheumatoid arthritis and healthy controls imaged by high-resolution peripheral quantitative computed tomography. *J Rheumatol* 2016;43:1914–20.
11. Schett G, Gravallesse E. Bone erosion in rheumatoid arthritis: mechanisms, diagnosis and treatment. *Nat Rev Rheumatol* 2012;8:656–64.
12. Binks DA, Gravallesse EM, Bergin D, Hodgson RJ, Tan AL, Matzelle MM, et al. Role of vascular channels as a novel mechanism for subchondral bone damage at cruciate ligament entheses in osteoarthritis and inflammatory arthritis. *Ann Rheum Dis* 2015;74:196–203.
13. Schett G, Stolina M, Bolon B, Middleton S, Adlam M, Brown H, et al. Analysis of the kinetics of osteoclastogenesis in arthritic rats. *Arthritis Rheum* 2005;52:3192–201.
14. Paleolog EM. The vasculature in rheumatoid arthritis: cause or consequence? *Int J Exp Pathol* 2009;90:249–61.
15. Kleyer A, Finzel S, Rech J, Manger B, Krieter M, Faustini F, et al. Bone loss before the clinical onset of rheumatoid arthritis in subjects with anticitrullinated protein antibodies. *Ann Rheum Dis* 2014;73:854–60.
16. Koh JH, Jung SM, Lee JJ, Kang KY, Kwok S-K, Park S-H, et al. Radiographic structural damage is worse in the dominant than the non-dominant hand in individuals with early rheumatoid arthritis. *PLoS One* 2015;10:e0135409.
17. Srikkum W, Virayavanich W, Burghardt AJ, Yu A, Link TM, Imboden JB, et al. Quantitative and semiquantitative bone erosion assessment on high-resolution peripheral quantitative computed tomography in rheumatoid arthritis. *J Rheumatol* 2013;40:408–16.
18. Owsianik WD, Kundi A, Whitehead JN, Kraag GR, Goldsmith C. Radiological articular involvement in the dominant hand in rheumatoid arthritis. *Ann Rheum Dis* 1980;39:508–10.
19. Aletaha D, Neogi T, Silman AJ, Funovits J, Felson DT, Bingham CO 3rd, et al. 2010 Rheumatoid arthritis classification criteria: an American College of Rheumatology/European League Against Rheumatism collaborative initiative. *Arthritis Rheum* 2010;62:2569–81.
20. Barnabe C, Feehan L. High-resolution peripheral quantitative computed tomography imaging protocol for metacarpophalangeal joints in inflammatory arthritis: the SPECTRA collaboration. *J Rheumatol* 2012;39:1494–5.
21. Piatat JB, Burghardt AJ, Sode M, Link TM, Majumdar S. Visual grading of motion induced image degradation in high resolution

- peripheral computed tomography: impact of image quality on measures of bone density and micro-architecture. *Bone* 2012;50:111–18.
22. van der Heijde D. How to read radiographs according to the Sharp/van der Heijde method. *J Rheumatol* 2000;27:261–3.
 23. Haavardsholm EA, Bøyesen P, Østergaard M, Schildvold A, Kvien TK. Magnetic resonance imaging findings in 84 patients with early rheumatoid arthritis: bone marrow oedema predicts erosive progression. *Ann Rheum Dis* 2008;67:794–800.
 24. Courvoisier N, Dougados M, Cantagrel A, Goupille P, Meyer O, Sibilia J, et al. Prognostic factors of 10-year radiographic outcome in early rheumatoid arthritis: a prospective study. *Arthritis Res Ther* 2008;10:R106.
 25. Finzel S, Rech J, Schmidt S, Engelke K, Englbrecht M, Stach C, et al. Repair of bone erosions in rheumatoid arthritis treated with tumour necrosis factor inhibitors is based on bone apposition at the base of the erosion. *Ann Rheum Dis* 2011;70:1587–93.
 26. van der Heijde D. Radiographic progression in rheumatoid arthritis: does it reflect outcome? Does it reflect treatment? *Ann Rheum Dis* 2001;60(Suppl 3):iii47–50.
 27. Scharnga A, Keller KK, Peters M, van Tubergen A, van den Bergh JP, van Rietbergen B, et al. Vascular channels in metacarpophalangeal joints: a comparative histologic and high-resolution imaging study. *Sci Rep* 2017;7:8966.
 28. Werner D, Simon D, Englbrecht M, Stemmler F, Simon C, Berlin A, et al. Rheumatoid arthritis is characterized by early changes of the cortical micro-channel (CoMiC) system in the bare area of the joints. *Arthritis Rheumatol* 2017;69:1580–7.
 29. Sharp JT, Wolfe F, Lassere M, Boers M, Van Der Heijde D, Larsen A, et al. Variability of precision in scoring radiographic abnormalities in rheumatoid arthritis by experienced readers. *J Rheumatol* 2004;31:1062–72.