

Quality of vision after ultrathin descemet stripping automated endothelial keratoplasty

Citation for published version (APA):

Dickman, M. M., Dunker, S. L., Kruit, P. J., Remeijer, L., van Rooij, J., van der Lelij, A., Wijdh, R. H. J., van den Biggelaar, F. J. H. M., Berendschot, T. T. J. M., van den Berg, T. J. T. P., & Nuijts, R. M. M. A. (2019). Quality of vision after ultrathin descemet stripping automated endothelial keratoplasty: a multicentre randomized clinical trial. *Acta Ophthalmologica*, 97(4), E671-E672. <https://doi.org/10.1111/aos.14019>

Document license:

TAVERNE

DOI:

[10.1111/aos.14019](https://doi.org/10.1111/aos.14019)

Document status and date:

Published: 01/06/2019

Document Version:

Publisher's PDF, also known as Version of Record (includes final page, issue and volume numbers)

Please check the document version of this publication:

- A submitted manuscript is the version of the article upon submission and before peer-review. There can be important differences between the submitted version and the official published version of record. People interested in the research are advised to contact the author for the final version of the publication, or visit the DOI to the publisher's website.
- The final author version and the galley proof are versions of the publication after peer review.
- The final published version features the final layout of the paper including the volume, issue and page numbers.

[Link to publication](#)

General rights

Copyright and moral rights for the publications made accessible in the public portal are retained by the authors and/or other copyright owners and it is a condition of accessing publications that users recognise and abide by the legal requirements associated with these rights.

- Users may download and print one copy of any publication from the public portal for the purpose of private study or research.
- You may not further distribute the material or use it for any profit-making activity or commercial gain
- You may freely distribute the URL identifying the publication in the public portal.

If the publication is distributed under the terms of Article 25fa of the Dutch Copyright Act, indicated by the "Taverne" license above, please follow below link for the End User Agreement:

www.tue.nl/taverne

Take down policy

If you believe that this document breaches copyright please contact us at:

openaccess@tue.nl

providing details and we will investigate your claim.

injection pain, burning, lacrimation, redness and gritty sensation. Each of the discomfort type was graded for each eye on a 4-point scale: None, mild, moderate and severe.

We found no significant difference in the patient-reported discomfort in the irrigated eyes versus the non-irrigated eyes regarding pain (p-value = 1.000), burning (p-value = 0.879), lacrimation (p-value = 0.862), redness (p-value = 1.0) or gritty sensation (p-value = 0.426). When analysing the slit-lamp images, we found that the irrigated eyes showed significantly less epithelial staining (p-value = 0.007, Fisher's exact test), as shown in Fig. 1C,D.

Whether or not these findings hold clinical consequences remains to be elucidated. A limitation to the present study is the lack of follow-up images, as we are unable to tell how long the epithelial defects persist.

In conclusion, we found that irrigation of the eye and removal of PI after ended IVI procedure caused significant less corneal epithelial defects. Epithelial defects can potentially make the eye susceptible for corneal pathogens and may lead to keratitis. Presumably, the epithelial defects in relation to the use of PI heal quickly, since there is no difference in patient-reported discomfort. Routine irrigation for the purpose of reducing post-IVI discomfort is therefore not recommended.

References

- Grzybowski A, Kanclerz P & Myers WG (2018a): Review: the use of povidone-iodine in ophthalmology. *Curr Opin Ophthalmol* **29**: 19–32.
- Grzybowski A, Told R, Sacu S, Bandello F, Moisseiev E, Loewenstein A & Schmidt-Erfurth U (2018b): 2018 Update on intravitreal injections: euretina expert consensus recommendations. *Ophthalmologica* **239**: 181–193.
- Jiang J, Wu M & Shen T (2009): The toxic effect of different concentrations of povidone iodine on the rabbit's cornea. *Cutan Ocul Toxicol* **28**: 119–124.
- Merani R & Hunyor AP (2015): Endophthalmitis following intravitreal anti-vascular endothelial growth factor (VEGF) injection: a comprehensive review. *Int J Retina Vitreous* **21**: 1.
- Miyata K, Amano S, Sawa M & Nishida T (2003): A novel grading method for superficial punctate keratopathy magnitude and its correlation with corneal epithelial permeability. *Arch Ophthalmol* **121**: 1537–1539.
- Correspondence:
Sofie Jandorf, MD
Clinical Eye Research Division
Department of Ophthalmology
Zealand University Hospital
Vestermarksvej 23
DK-4000 Roskilde
Denmark
Tel: +45 4732 3900
Fax: +45 4636 2645
Email: sofie@jandorf.dk
- Quality of vision after ultrathin descemet stripping automated endothelial keratoplasty: a multicentre randomized clinical trial**
- Mor M. Dickman,¹  Suryan L. Dunker,¹ Pieter J. Kruit,² Lies Remeijer,³ Jeroen van Rooij,³ Allegonda van der Lelij,⁴ Robert H. J. Wijdh,⁵ Frank J. H. M. van den Biggelaar,¹ Tos T. J. M. Berendschot,¹ Thomas J. T. P. van den Berg⁶ and Rudy M. M. A. Nuijts¹
- ¹University Eye Clinic, Maastricht University Medical Center+, Maastricht, the Netherlands; ²ETB-BISLIFE, Leiden, the Netherlands; ³Rotterdam Eye Hospital, Rotterdam, the Netherlands; ⁴Department of Ophthalmology, University Medical Center Utrecht, Utrecht, the Netherlands; ⁵Department of Ophthalmology, University Medical Center Groningen, Groningen, the Netherlands; ⁶The Netherlands Institute for Neuroscience, Amsterdam, the Netherlands
- doi: 10.1111/aos.14019
- Editor,
In the era of modern endothelial keratoplasty (EK), focus is gradually shifting from graft survival and visual acuity (VA) to quality of vision and patient-reported outcome measures. Patients routinely seek treatment for symptoms such as glare disability and reduced contrast sensitivity – parameters unrelated to VA. Indeed, VA only represents the small angle domain of the retinal point spread function while straylight (a measure of glare disability) and contrast
- sensitivity capture the large angle domain (Fig. 1A) (Van den Berg et al. 2009). Recent studies comparing EK techniques found only small differences in best-corrected VA, underscoring the need to define an objective approximation of the entire visual function and well-being.
- In this letter, we report a prespecified secondary analysis of different aspects of quality of vision and vision-related quality of life from a prospective multicentre randomized controlled trial (RCT) comparing patients with Fuchs endothelial corneal dystrophy randomized to either ultrathin descemet stripping automated EK (UT-DSAEK) or DSAEK. The study design has previously been described in detail (Dickman et al. 2016).
- We measured corneal higher-order aberrations (HOAs), straylight and contrast sensitivity using the Pentacam HR Scheimpflug camera (OCULUS Optikgeräte GmbH, Wetzlar, Germany), C-Quant straylight metre (OCULUS Optikgeräte GmbH) and the CSV-1000 chart (Vector vision Inc., Greenville, OH, USA), respectively.
- We used a linear mixed model with the respective mean outcome variable as the dependent variable, and time, study groups and their interaction as covariates. Bivariate relationships were calculated using Pearson correlation analysis. Results are shown as means with 95% confidence intervals in parenthesis, unless otherwise specified. We considered a p value of <0.05 statistically significant.
- Anterior corneal HOAs did not significantly differ between the groups at all time-points. In contrast, posterior corneal HOAs values were lower for UT-DSAEK compared to DSAEK at 3 months [0.55 (0.45–0.66) versus 0.78 (0.61–0.95); p = 0.03] and comparable thereafter. Straylight was also elevated before surgery in both groups (Fig. 1B) (Van den Berg et al. 2007). Interestingly, we found a significant negative correlation between patient age and straylight before surgery ($r = -0.35$; p = 0.011), suggesting increased straylight may drive young Fuchs' patients to seek treatment. After surgery, straylight returned to age-normative values in both treatment groups (Fig. 1B) (Łabuz et al. 2015). Contrast sensitivity returned to age-normative values 3 months after UT-DSAEK [log (CS) = 1.34 (1.2–1.47), UT-DSAEK

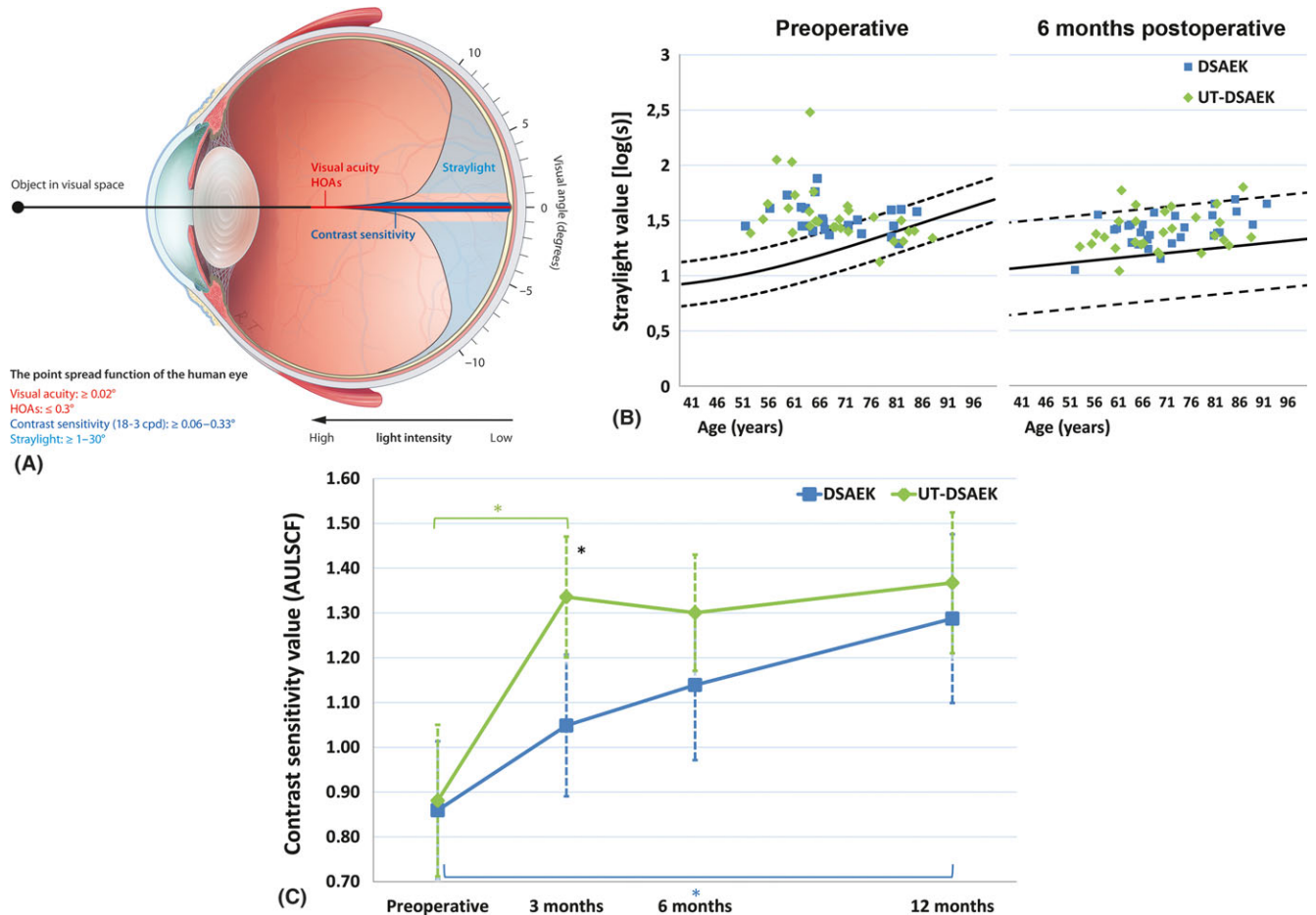


Fig. 1. (A) Schematic retinal point spread function showing visual domains of visual acuity, HOAs, contrast sensitivity and straylight in the human eye. The visual angle is exaggerated for clarity. (B) Intraocular straylight as a function of age in DSAEK and UT-DSAEK before surgery (left) and 6 months after surgery (right). Lines represent mean straylight values \pm 95% confidence interval for phakic eyes (left) and pseudophakic eyes (right) (Van den Berg et al. 2007; Labuz et al. 2015). (C). Contrast sensitivity in DSAEK and UT-DSAEK at baseline, and 3, 6 and 12 months postoperatively. *p < 0.05. AULSCF = area under the log contrast sensitivity curve; Cpd = cycles per degree; DSAEK = descemet stripping automated endothelial keratoplasty; HOAs = higher-order aberrations; UT-DSAEK = ultrathin descemet stripping automated endothelial keratoplasty.

versus $\log(\text{CS}) = 1.05$ (0.89–1.21), DSAEK; $p = 0.009$] and 12 months after DSAEK [$\log(\text{CS}) = 1.37$ (1.21–1.52), UT-DSAEK versus $\log(\text{CS}) = 1.29$ (1.1–1.48), DSAEK; $p = 0.53$; Fig. 1C] (Hashemi et al. 2012).

Vision-related quality of life was assessed using the 25-item National Eye Institute Visual Functioning Questionnaire (VFQ-25). No differences between the groups were observed at all time-points. The composite score of the VFQ-25 increased significantly 3 months after surgery [$\beta = 12$ (9–14); $p < 0.001$] and improved further 12 months after surgery [$\beta = 3$ (1–6); $p = 0.02$]. This improvement is clinically relevant on the basis of previous studies, suggesting a cut-off value of ten points (Lindblad & Clemons 2005).

In conclusion, this RCT showed both DSAEK and UT-DSAEK result in comparable improvements in quality of

vision and vision-related quality of life. These results can serve a valuable reference for future studies as the treatment for Fuchs' continues to evolve.

References

Dickman MM, Kruit PJ, Remeijer L et al. (2016): A randomized multicenter clinical trial of ultrathin descemet stripping automated endothelial keratoplasty (DSAEK) versus DSAEK. *Ophthalmology* **123**: 2276–2284.

Hashemi H, Khabazkhoob M, Jafarzadehpur E, Emamian MH, Shariati M & Fotouhi A (2012): Contrast sensitivity evaluation in a population-based study in Shahroud, Iran. *Ophthalmology* **119**: 541–546.

Labuz G, Reus NJ & van den Berg TJTP (2015): Ocular straylight in the normal pseudophakic eye. *J Cataract Refract Surg* **41**: 1406–1415.

Lindblad AS & Clemons TE (2005): Responsiveness of the National Eye Institute Visual

Function Questionnaire to progression to advanced age-related macular degeneration, vision loss, and lens opacity: AREDS Report no. 14. *Arch Ophthalmol* (Chicago, IL.: 1960) **123**: 1207–1214.

Van den Berg TJ, Van Rijn LJ, Michael R et al. (2007): Straylight effects with aging and lens extraction. *Am J Ophthalmol* **144**: 358–363.

Van den Berg TJ, Franssen L & Coppens JE (2009): Straylight in the human eye: testing objectivity and optical character of the psychophysical measurement. *Ophthalmic Physiol Opt* **29**: 345–350.

Correspondence:

Mor M. Dickman
University Eye Clinic
Maastricht University Medical Center +
Postbus 6202 AZ, Maastricht
the Netherlands
Tel: +31 (0) 43 387 6543
Fax: +31 (0) 43 387 5343
Email: mor.dickman@mumc.nl