

What Is the Diagnostic Performance of Conventional Radiographs and Clinical Reassessment Compared With HR-pQCT Scaphoid Fracture Diagnosis?

Citation for published version (APA):

Daniels, A. M., Kranendonk, J., Wyers, C. E., Janzing, H. M. J., Sassen, S., van Rietbergen, B., Geusens, P. P. M. M., Kaarsemaker, S., Hannemann, P. F. W., Poeze, M., & van den Bergh, J. P. (2023). What Is the Diagnostic Performance of Conventional Radiographs and Clinical Reassessment Compared With HR-pQCT Scaphoid Fracture Diagnosis? *Clinical Orthopaedics and Related Research*, 481(1), 97-104. <https://doi.org/10.1097/CORR.0000000000002310>

Document license:
TAVERNE

DOI:
[10.1097/CORR.0000000000002310](https://doi.org/10.1097/CORR.0000000000002310)

Document status and date:
Published: 01/01/2023

Document Version:
Publisher's PDF, also known as Version of Record (includes final page, issue and volume numbers)

Please check the document version of this publication:

- A submitted manuscript is the version of the article upon submission and before peer-review. There can be important differences between the submitted version and the official published version of record. People interested in the research are advised to contact the author for the final version of the publication, or visit the DOI to the publisher's website.
- The final author version and the galley proof are versions of the publication after peer review.
- The final published version features the final layout of the paper including the volume, issue and page numbers.

[Link to publication](#)

General rights

Copyright and moral rights for the publications made accessible in the public portal are retained by the authors and/or other copyright owners and it is a condition of accessing publications that users recognise and abide by the legal requirements associated with these rights.

- Users may download and print one copy of any publication from the public portal for the purpose of private study or research.
- You may not further distribute the material or use it for any profit-making activity or commercial gain
- You may freely distribute the URL identifying the publication in the public portal.

If the publication is distributed under the terms of Article 25fa of the Dutch Copyright Act, indicated by the "Taverne" license above, please follow below link for the End User Agreement:

www.tue.nl/taverne

Take down policy


If you believe that this document breaches copyright please contact us at:

openaccess@tue.nl

providing details and we will investigate your claim.

Clinical Research

What Is the Diagnostic Performance of Conventional Radiographs and Clinical Reassessment Compared With HR-pQCT Scaphoid Fracture Diagnosis?

Anne M. Daniels MD^{1,2} , Josephine Kranendonk MD¹, Caroline E. Wyers PhD^{2,3,4}, Heinrich M. J. Janzing MD, PhD¹, Sander Sassen MD⁵, Bert van Rietbergen PhD^{6,7}, Piet P. M. M. Geusens MD, PhD^{7,8}, Sjoerd Kaarsemaker MD⁹, Pascal F. W. Hannemann MD, PhD¹⁰, Martijn Poeze MD, PhD^{2,10}, Joop P. van den Bergh MD, PhD^{2,3,4}

Received: 29 October 2020 / Accepted: 14 June 2022 / Published online: 13 July 2022
Copyright © 2022 by the Association of Bone and Joint Surgeons

Abstract

Background Conventional radiographs and clinical reassessment are considered guides in managing clinically suspected scaphoid fractures. This is a unique study as it assessed the value of conventional radiographs and clinical reassessment in a cohort of patients, all of whom underwent additional imaging, regardless of the outcome of conventional radiographs and clinical reassessment.

Questions/purposes (1) What is the diagnostic performance of conventional radiographs in patients with a clinically suspected scaphoid fracture compared with high-resolution peripheral quantitative CT (HR-pQCT)? (2) What is the diagnostic performance of clinical reassessment in patients with a clinically suspected scaphoid fracture compared with HR-pQCT? (3) What is the diagnostic performance of conventional radiographs and

clinical reassessment combined compared with HR-pQCT?

Methods Between December 2017 and October 2018, 162 patients with a clinically suspected scaphoid fracture presented to the emergency department (ED). Forty-six patients were excluded and another 25 were not willing or able to participate, which resulted in 91 included patients. All patients underwent conventional radiography in the ED and clinical reassessment 7 to 14 days later, together with CT and HR-pQCT. The diagnostic performance characteristics and accuracy of conventional radiographs and clinical reassessment were compared with those of HR-pQCT for the diagnosis of fractures since this was proven to be superior to CT scaphoid fracture detection. The cohort included 45 men and 46 women with a median (IQR) age of 52 years (29 to 67). Twenty-four patients with a median age of 44 years (35 to 65) were diagnosed with a scaphoid fracture on HR-pQCT.

Results When compared with HR-pQCT, conventional radiographs alone had a sensitivity of 67% (95% CI 45% to 84%), specificity of 85% (95% CI 74% to 93%), positive predictive value (PPV) of 62% (95% CI 46% to 75%), negative predictive value (NPV) of 88% (95% CI 80% to 93%), and a positive and negative likelihood ratio (LR) of 4.5 (95% CI 2.4 to 8.5) and 0.4 (95% CI 0.2 to 0.7), respectively. Compared with HR-pQCT, clinical reassessment alone resulted in a sensitivity of 58% (95% CI 37% to 78%), specificity of 42% (95% CI 30% to 54%), PPV of 26% (95% CI 19% to 35%), NPV of 74% (95% CI 62% to 83%), as well as a positive and negative LR of 1.0 (95% CI 0.7 to 1.5) and 1.0 (95% CI 0.6 to 1.7), respectively. Combining clinical examination with

One of the authors (AMD) certifies receipt of personal payments or benefits, during the study period, in an amount of USD 10,000 to USD 100,000 from the VieCuri trust for research and innovation. One of the authors (BvR) is a consultant for Scanco Medical AG. All ICMJE Conflict of Interest Forms for authors and *Clinical Orthopaedics and Related Research*® editors and board members are on file with the publication and can be viewed on request. *Clinical Orthopaedics and Related Research*® neither advocates nor endorses the use of any treatment, drug, or device. Readers are encouraged to always seek additional information, including FDA approval status, of any drug or device before clinical use. Ethical approval for this study was obtained from VieCuri Medical Centre, Venlo, the Netherlands (approval number NL 62476.068.17). This study was performed at the VieCuri Medical Centre, Venlo, the Netherlands.

conventional radiography produced a sensitivity of 50% (95% CI 29% to 71%), specificity of 91% (95% CI 82% to 97%), PPV of 67% (95% CI 46% to 83%), NPV of 84% (95% CI 77% to 88%), as well as a positive and negative LR of 5.6 (95% CI 2.4 to 13.2) and 0.6 (95% CI 0.4 to 0.8), respectively.

Conclusion The accuracy of conventional radiographs (80% compared with HR-pQCT) and clinical reassessment (46% compared with HR-pQCT) indicate that the value of clinical reassessment is limited in diagnosing scaphoid fractures and cannot be considered directive in managing scaphoid fractures. The combination of conventional radiographs and clinical reassessment does not increase the accuracy of these diagnostic tests compared with the accuracy of conventional radiographs alone and is therefore also limited in diagnosing scaphoid fractures.

Level of Evidence Level II, diagnostic study.

Introduction

Diagnosing scaphoid fractures is challenging because of the unique shape, size, and orientation of this carpal bone. Various imaging techniques have been suggested for the improvement of diagnosis. Currently, CT, MRI, and bone scintigraphy (BS) are the most frequently used imaging techniques, but they all have limitations [1, 8, 10, 12, 20, 21, 24, 26, 30, 32, 36, 38, 45-47, 50]. Because of varying diagnostic performance results, no true reference standard exists regarding the preferred imaging technique.

Clinical suspicion is most often based on tenderness in the anatomic snuffbox after a fall on an outstretched

hand [22, 23]. Conventional radiography is performed at the emergency department (ED) but is insufficient to exclude a scaphoid fracture because 20% to 40% of patients with normal initial radiographic findings have a fracture on additional imaging, according to existing studies [3, 14, 23-25, 29]. Therefore, regardless of the outcome of conventional radiography, patients with a clinically suspected scaphoid fracture are immobilized with a cast and reassessed within 1 to 2 weeks. If a scaphoid fracture is still suspected at the patient's clinical reassessment, additional imaging is performed to obtain a definite diagnosis [5, 9, 33, 46].

This is a unique study as it assessed the value of conventional radiographs and clinical reassessment in a cohort of patients subjected to additional imaging, regardless of the outcome of conventional radiographs and clinical reassessment. High-resolution peripheral quantitative CT (HR-pQCT), a novel imaging technique that allows an assessment of the microstructure of cortical and trabecular bone at the distal radius and tibia, has recently been introduced [11, 13, 17-19, 31, 39]. Because there is no consensus regarding the reference imaging technique for diagnosing scaphoid fractures, we have studied HR-pQCT as a diagnostic tool and have shown that it is feasible [7, 16] and superior [15] to CT for detecting fractures in patients with a clinically suspected scaphoid fracture. Therefore, we compared the results of conventional radiographs and clinical reassessment with HR-pQCT in this study.

In this study, we asked: (1) What is the diagnostic performance of conventional radiographs in patients with a clinically suspected scaphoid fracture compared with HR-pQCT? (2) What is the diagnostic performance of clinical

¹Department of Surgery, VieCuri Medical Centre, Venlo, the Netherlands

²NUTRIM School for Nutrition and Translational Research in Metabolism, Maastricht University, Maastricht, the Netherlands

³Department of Internal Medicine, VieCuri Medical Centre, Venlo, the Netherlands

⁴Department of Internal Medicine, Maastricht University Medical Centre, Maastricht, the Netherlands

⁵Department of Radiology, VieCuri Medical Centre, Venlo, the Netherlands

⁶Orthopaedic Biomechanics, Department of Biomedical Engineering, Eindhoven University of Technology, Eindhoven, the Netherlands

⁷Department of Orthopaedic Surgery, Research School CAPHRI, Maastricht University Medical Centre, Maastricht, the Netherlands

⁸Faculty of Medicine, Hasselt University, Belgium

⁹Department of Orthopaedic Surgery, VieCuri Medical Centre, Venlo, the Netherlands

¹⁰Department of Surgery, Subdivision of Trauma Surgery, Maastricht University Medical Centre, Maastricht, the Netherlands

A. M. Daniels ✉, Department of Surgery, VieCuri Medical Centre, Tegelseweg 210, 5912 BL, Venlo, the Netherlands, Email: adaniels@viecuri.nl

reassessment in patients with a clinically suspected scaphoid fracture compared with HR-pQCT? (3) What is the diagnostic performance of conventional radiographs and clinical reassessment combined compared with HR-pQCT?

Patients and Methods

Study Population and Design

In this prospective study, all patients 18 years or older with a clinically suspected scaphoid fracture who presented to the ED between December 2017 and October 2018 within 1 week after trauma were eligible for study participation. This yielded a total of 162 patients, of which 46 were excluded based on age younger than 18 years, mental disability, trauma more than 7 days before, or a previous scaphoid fracture. Another 25 patients were eligible but not willing or able to participate, resulting in 91 included patients (Fig. 1).

At the ED, conventional radiographs were obtained in four views: posteroanterior, true lateral, semipronated oblique, and posteroanterior with the wrist in ulnar deviation. Conventional radiographs were assessed by an experienced team of radiologists. Independent of the outcome of these radiography findings, cast immobilization was applied and patients received written study information from their treating physician in the ED. Standard outpatient visits were planned within 7 to 14 days after trauma (for patients for whom nonoperative treatment was appropriate) according to current clinical practice. If patients were eligible and willing to participate, informed consent was obtained during this visit, followed by a clinical examination and questionnaires, including pain and functioning scores, medical history, smoking status, alcohol use, medications, dominant hand, and trauma mechanism.

A surgical resident (AMD) conducted clinical reassessment and classified a finding as positive if at least one of the following was present: anatomic snuffbox tenderness, scaphoid tubercle tenderness, or axial compression pain on the thumb (with the thumb in extension and

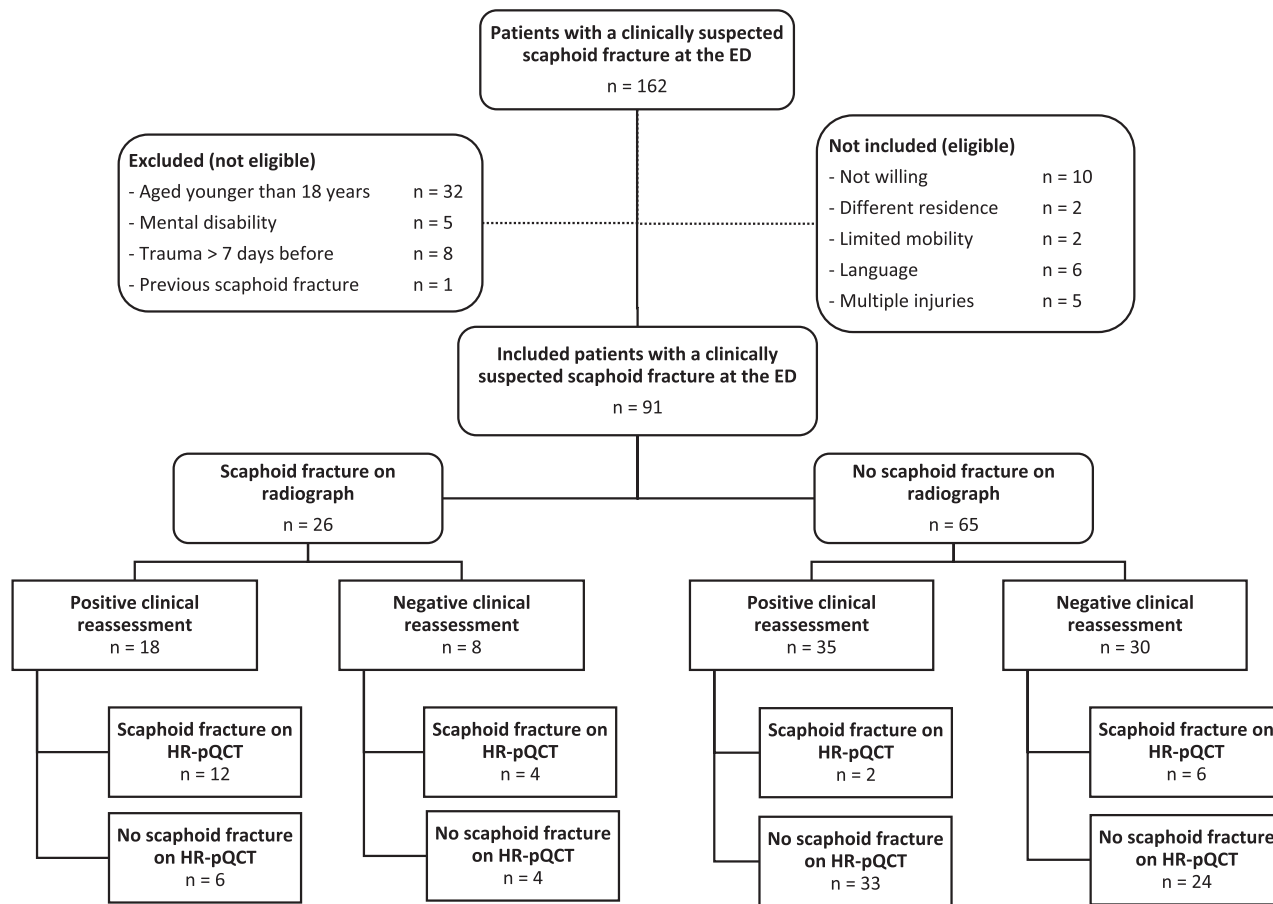


Fig. 1 This flowchart shows the patient selection, inclusion criteria, and results of this study.

abduction). This clinical workup was in accordance with regional treatment protocols and published studies [5, 9, 33, 46]. Conventional CT and HR-pQCT scanning of the scaphoid bone region was conducted on the same day, regardless of the outcome of clinical reassessment. As there is currently no true reference standard available, we compared the results of conventional radiographs and clinical reassessment to HR-pQCT because this technique was superior to conventional CT in our previously conducted study [15]. The radiologist and trauma surgeon assessing the CT and HR-pQCT were blinded to the other's assessment of the patients as well as to their clinical data.

Primary and Secondary Study Outcomes

Our primary study goal was to assess the diagnostic performance of conventional radiographs and clinical reassessment compared with HR-pQCT. We obtained conventional radiographs at initial presentation of all patients and conducted clinical reassessment at the outpatient clinic and compared this with the results of our chosen gold standard, HR-pQCT. Our secondary study goal was to assess the diagnostic performance of conventional radiographs and clinical reassessment combined compared with HR-pQCT. We combined the data and classified it as positive if a scaphoid fracture was seen on conventional radiographs and clinical reassessment was positive; we classified it as negative if there was no scaphoid fracture on conventional radiographs or clinical reassessment was negative.

Patient Characteristics

The median (IQR) age in our cohort, which consisted of 45 men and 46 women, was 52 years (29 to 67). The presence of a scaphoid fracture was suggested on the conventional radiographs of 29% (26 of 91) of patients, and 58% (53 of 91) of patients had clinical suspicion of a scaphoid fracture at reassessment. Overall, a scaphoid fracture was diagnosed in 26% (24 of 91) on HR-pQCT.

The median (IQR) age was lower in patients with a scaphoid fracture on HR-pQCT (44 years [35 to 65]) than in those without a scaphoid fracture (65 years [52 to 74]; $p = 0.001$). Fifteen of 24 patients with a scaphoid fracture on HR-pQCT were men.

HR-pQCT

HR-pQCT (XtremeCT II; Scanco Medical AG) scanning of the scaphoid bone was performed on a 30.6-mm region of the wrist (three consecutive 10.2-mm stacks with an isotropic voxel size of 0.061 mm), with a reference line at

the longitudinal sagittal ridge between the scaphoid bone and lunate fossa at the articular surface of the distal radius. The standard protocol of the distal radius, with an isotropic voxel size of 0.061 mm, was adapted to three consecutive stacks (30.6 mm) to cover the entire scaphoid [37, 42, 43].

All scanning was conducted with the wrist in a synthetic cast with a removable cast around the thumb, which was only applied during the HR-pQCT procedure for added stability. The patient's forearm was placed in an anatomically shaped motion-restraining holder to obtain a standardized position. Detailed information regarding the scanning procedures, image reconstruction, and fracture assessment was described previously [7, 15].

Ethical Approval

This study was approved by our medical ethics committee (NL 62476.068.17) and was conducted according to the principles of the Declaration of Helsinki and in accordance with the Medical Research Involving Human Subjects Act.

Statistical Analysis

We analyzed data using IBM SPSS Statistics, version 25.0 (IBM Corp). Categorical data are presented as frequencies with a percentage. Data distributions were tested with Q-Q plots and a Kolmogorov-Smirnov analysis. Normally distributed data have been presented as the mean and SD; nonnormally distributed data have been presented as the median and IQR. We used chi-square tests to analyze differences in patient characteristics between patients with a scaphoid fracture and those without a scaphoid fracture on HR-pQCT. The level of significance was set at $\alpha = 0.05$. The diagnostic performance characteristics of conventional radiographs and clinical reassessment, including sensitivity, specificity, positive predictive value (PPV) and negative predictive value (NPV), positive and negative likelihood ratio (LR), and accuracy were calculated using MedCalc, Clinical Online Calculator, diagnostic test evaluation calculator (MedCalc Software Ltd) compared with HR-pQCT.

Results

Conventional Radiographs

We found a sensitivity of 67% (95% CI 45% to 84%), specificity of 85% (95% CI 74% to 93%), PPV of 62% (95% CI 46% to 75%), NPV of 88% (95% CI 80% to 93%), as well as a positive and negative LR of 4.5 (95% CI 2.4 to 8.5) and 0.4 (95% CI 0.2 to 0.7), respectively, for conventional radiographs compared with HR-pQCT scaphoid

Table 1. Diagnostic performance characteristics of conventional radiographs at the ED and outpatient clinical reassessment 7 to 14 days later using HR-pQCT diagnosis as reference (scaphoid fracture vs no scaphoid fracture)

Diagnostic performance characteristic	Sensitivity	Specificity	PPV	NPV	Positive LR	Negative LR	AUC (95% CI)	p value
Radiograph vs HR-pQCT	67%	85%	62%	88%	4.5	0.4	0.76 (0.64-0.88)	< 0.001
Clinical reassessment vs HR-pQCT	58%	42%	26%	74%	1.0	1.0	0.50 (0.37-0.64)	0.99
Radiograph and clinical reassessment vs HR-pQCT	50%	91%	67%	84%	5.6	0.6	0.71 (0.57-0.84)	0.003

AUC = area under the curve.

fracture diagnosis (Table 1). Eight of 24 patients with scaphoid fractures diagnosed with HR-pQCT did not have a scaphoid fracture on conventional radiographs, and 10 patients were diagnosed with a scaphoid fracture on conventional radiographs, although they appeared to have no fracture on HR-pQCT.

Clinical Reassessment

We found a sensitivity of 58% (95% CI 37% to 78%), specificity of 42% (95% CI 30% to 54%), PPV of 26% (95% CI 19% to 35%), NPV of 74% (95% CI 62% to 83%), as well as a positive and negative LR of 1.0 (95% CI 0.7 to 1.5) and 1.0 (95% CI 0.6 to 1.7), respectively (Table 1). Clinical reassessment results were negative in 10 of 24 patients with a scaphoid fracture on HR-pQCT and positive in 39 patients without a scaphoid fracture on HR-pQCT. Of 39 patients with a positive clinical reassessment result without a scaphoid fracture on HR-pQCT, nine had a diagnosis of a nondisplaced fracture of one of the other carpal bones, and two had a fracture of the distal radius.

Conventional Radiographs and Clinical Reassessment Combined

The combination of conventional radiographs and clinical reassessment resulted in the following diagnostic performance characteristics compared with HR-pQCT: sensitivity of 50% (95% CI 29% to 71%), specificity of 91% (95% CI 82% to 97%), PPV of 67% (95% CI 46% to 83%), NPV of 84% (95% CI 77% to 88%), as well as a positive and negative LR of 5.6 (95% CI 2.4 to 13.2) and 0.6 (95% CI 0.4 to 0.8), respectively (Table 1).

Discussion

The unique shape, size, and orientation of the carpal bone makes diagnosing scaphoid fractures a challenge. Further, the varied diagnostic performance of the most commonly

used imaging techniques—CT, MRI, and BS—results in the absence of a true reference standard.

Conventional radiography performed in the ED often falls short when diagnosing scaphoid fractures: 20% to 40% of patients with normal initial radiographic findings are found to have a fracture on additional imaging [3, 14, 23-25, 29]. Consequently, regardless of imaging results, patients with a clinically suspected scaphoid fracture are immobilized with a cast and reassessed within 1 to 2 weeks. If a scaphoid fracture is still suspected at the clinical reassessment, additional imaging is performed to obtain a definite diagnosis [5, 9, 33, 46].

In our study, we evaluated the diagnostic performance of conventional radiographs and clinical reassessment in a cohort of patients with clinically suspected scaphoid fractures. We found that clinical reassessment had limited value in diagnosing scaphoid fractures, and it cannot be considered directive in managing these injuries. Further, combining conventional radiographs and clinical reassessment does not increase the accuracy of these diagnostic tests compared with the accuracy of conventional radiographs alone; therefore, they are also limited in diagnosing scaphoid fractures.

Limitations

This study is limited because HR-pQCT is not yet readily available in a hospital setting because it is exclusively used as research tool. As the patients in our study were selected from a group of consecutive patients from the ED who all underwent HR-pQCT, we are convinced that this does not affect our results. Although this limited availability may complicate research involving the HR-pQCT in the near future, implementation in a hospital setting will follow in the upcoming years, and thereby this limitation will be overcome. Furthermore, other fractures were detected on additional imaging. The presence of fractures (other than scaphoid fractures) may influence the clinical assessment findings since patients might experience pain as a result of this other fracture interfering with the assessment for scaphoid fractures, as known from previously conducted

studies [12, 28, 29]. In our study, other nondisplaced carpal fractures or distal radius fractures were present in 11 of 39 patients with positive clinical reassessment results (without a scaphoid fracture on HR-pQCT). Third, given that there were only 24 patients with a scaphoid fracture, the 95% CIs of mainly the sensitivity and PPV rates were wider, and therefore, the uncertainty is greater for those values. However, we believe there is still enough perspective to make decisions about the utility of these diagnostics.

Conventional Radiographs

Conventional radiographs can be helpful to diagnose other fractures but are insufficient to diagnose scaphoid fractures without any additional imaging. Although the value of conventional radiographs has been studied frequently in the past [2, 4, 8, 10], comparing the results is difficult because of variation in the reference standard that was used. Overall, 20% to 40% of scaphoid fractures are initially occult on conventional radiographs [25, 38, 40, 48]. This is similar to the 33% proportion we found compared with HR-pQCT in our study. Because initially occult fractures are the focus of most studies, patients with positive conventional radiographic findings are not considered. This results in the absence of adequate diagnostic performance characteristics regarding false-positive radiographic diagnoses. If these patients were thought to have a scaphoid fracture without additional imaging, they would be immobilized unnecessarily, resulting in concurrent physical and socioeconomic consequences. In our opinion, the suggestion of a scaphoid fracture on conventional radiographs in the ED justifies early second-line imaging to confirm the diagnosis and assess the anatomic position of the fracture to rule out displacement or proximal pole localization or to reject the diagnosis of a scaphoid fracture. However, studies have used repeated conventional radiographs, an unreliable method, as the reference standard [32, 50].

Clinical Reassessment

The diagnostic accuracy of a clinical assessment for detecting suspected scaphoid fractures is limited. A large number of physical examination tests have been described to support diagnosing scaphoid fractures. The most common tests evaluate for tenderness in the anatomic snuffbox, scaphoid tubercle tenderness, and axial compression pain of the thumb [6, 12, 27, 34]. In a systematic review and meta-analysis [34], sensitivity ranges appeared to be relatively high, whereas specificity results were poor for tenderness in the anatomic snuffbox and axial compression on

the thumb. We think that in contrast to Unay et al. [49], the focus of a clinical assessment should be to minimize missed scaphoid fractures instead of preventing unnecessary additional imaging. In our study, we combined the diagnostic findings and classified patients as having positive findings if at least one of these findings was positive at clinical reassessment. Despite this low threshold, we identified more missed diagnoses ($n = 10$) compared with HR-pQCT if patients with negative clinical examination findings did not receive additional imaging.

Conventional Radiographs and Clinical Reassessment Combined

The combination of conventional radiographs and clinical reassessment does not increase the accuracy of these diagnostic tests compared with the accuracy of conventional radiographs alone. Some studies combined clinical tests or developed a clinical decision rule to increase the post-test fracture probability [6, 23, 35, 41, 44]. However, the proportion for predicting a true fracture remains relatively low (40%) [23], and implementation in daily practice is not always feasible because of the extensiveness and difficulty of the tests that are used [44]. Tenderness in the anatomic snuffbox is the most sensitive clinical diagnostic test but is insufficient to safely rule out a scaphoid fracture.

Conclusion

Based on our study results and the results of a previously mentioned review [34] with varying and disappointing diagnostic performance values, we conclude that clinical assessment is an inadequate indicator of the presence or absence of scaphoid fractures. We acknowledge that clinical investigation remains important in daily practice and that part of this assessment is useful; however, deciding to dismiss a patient from further follow-up with a 33% (HR-pQCT) chance of having a scaphoid fracture is not desirable. Therefore, clinical assessment alone cannot be considered directive in managing scaphoid fractures. The combination of conventional radiographs and clinical reassessment does not increase the accuracy of these diagnostic tests compared with the accuracy of conventional radiographs alone and is therefore also limited in diagnosing scaphoid fractures. Given that clinical reassessment is only 50% accurate, we suggest that additional imaging should not be conducted in addition to or based upon clinical reassessment but should rather immediately replace the current clinical reassessment. By introducing early additional imaging (high-resolution CT) in all patients instead of decision making (including the decision to perform imaging) based on clinical reassessment, the time

to definite diagnosis will be accelerated and decisions on treatment can be made more reliably.

References

- Adey L, Souer JS, Lozano-Calderon S, Palmer W, Lee SG, Ring D. Computed tomography of suspected scaphoid fractures. *J Hand Surg Am*. 2007;32:61-66.
- Balci A, Basara I, Cekdemir EY, et al. Wrist fractures: sensitivity of radiography, prevalence, and patterns in MDCT. *Emerg Radiol*. 2015;22:251-256.
- Beeres FJ, Hogervorst M, den Hollander P, Rhemrev S. Outcome of routine bone scintigraphy in suspected scaphoid fractures. *Injury*. 2005;36:1233-1236.
- Beeres FJ, Rhemrev SJ, den Hollander P, et al. Early magnetic resonance imaging compared with bone scintigraphy in suspected scaphoid fractures. *J Bone Joint Surg Br*. 2008;90:1205-1209.
- Beeres FJ, Rhemrev SJ, Hogervorst M, den Hollander P, Jukema GN. Scaphoid fractures: diagnosis and therapy [in Dutch]. *Ned Tijdschr Geneesk*. 2007;151:742-747.
- Bergh TH, Lindau T, Soldal LA, et al. Clinical scaphoid score (CSS) to identify scaphoid fracture with MRI in patients with normal x-ray after a wrist trauma. *Emerg Med J*. 2014;31:659-664.
- Beyers M, Daniels AM, Wyers CE, et al. The feasibility of high-resolution peripheral quantitative computed tomography (HR-pQCT) in patients with suspected scaphoid fractures. *J Clin Densitom*. 2020;23:432-444.
- Breitseher MJ, Metz VM, Gilula LA, et al. Radiographically occult scaphoid fractures: value of MR imaging in detection. *Radiology*. 1997;203:245-250.
- Buijze GA. Scaphoid fractures: anatomy, diagnosis and treatment. In: *Faculty of Medicine (AMC-UvA)*. University of Amsterdam; 2012.
- Buijze GA, Jorgsholm P, Thomsen NO, Bjorkman A, Besjakov J, Ring D. Diagnostic performance of radiographs and computed tomography for displacement and instability of acute scaphoid waist fractures. *J Bone Joint Surg Am*. 2012;94:1967-1974.
- Burghardt AJ, Krug R, Majumdar S. High-resolution imaging techniques for bone quality assessment. In: Feldman D, Pike JW, Bouillon R, Giovannucci E, Goltzman D, Hewison M, eds. *Vitamin D*. 4th ed. Elsevier; 2018:1007-1041.
- Carpenter CR, Pines JM, Schuur JD, Muir M, Calfee RP, Raja AS. Adult scaphoid fracture. *Acad Emerg Med*. 2014;21:101-121.
- Cheung AM, Adachi JD, Hanley DA, et al. High-resolution peripheral quantitative computed tomography for the assessment of bone strength and structure: a review by the Canadian Bone Strength Working Group. *Curr Osteoporos Rep*. 2013;11:136-146.
- Cheung GC, Lever CJ, Morris AD. X-ray diagnosis of acute scaphoid fractures. *J Hand Surg Br*. 2006;31:104-109.
- Daniels AM, Beyers M, Sassen S, et al. Improved detection of scaphoid fractures with high-resolution peripheral quantitative CT compared with conventional CT. *J Bone Joint Surg Am*. 2020;16:2138-2145.
- Daniels AM, Wyers CE, Janzing HMJ, et al. The interobserver reliability of the diagnosis and classification of scaphoid fractures using high-resolution peripheral quantitative CT. *Bone Joint J*. 2020;102:478-484.
- de Jong JJ, Willems PC, Arts JJ, et al. Assessment of the healing process in distal radius fractures by high resolution peripheral quantitative computed tomography. *Bone*. 2014;64:65-74.
- de Jong JJA, Arts JJC, Willems PC, et al. Contra-lateral bone loss at the distal radius in postmenopausal women after a distal radius fracture: a two-year follow-up HRpQCT study. *Bone*. 2017;101:245-251.
- de Jong JJA, Heyer FL, Arts JJC, et al. Fracture repair in the distal radius in postmenopausal women: a follow-up 2 years postfracture using HRpQCT. *J Bone Miner Res*. 2016;31:1114-1122.
- de Zwart AD, Beeres FJ, Rhemrev SJ, Bartlema K, Schipper IB. Comparison of MRI, CT and bone scintigraphy for suspected scaphoid fractures. *Eur J Trauma Emerg Surg*. 2016;42:725-731.
- de Zwart AD, Beeres FJ, Ring D, et al. MRI as a reference standard for suspected scaphoid fractures. *Br J Radiol*. 2012;85:1098-1101.
- Dias J, Kantharuban S. Treatment of scaphoid fractures: European approaches. *Hand Clin*. 2017;33:501-509.
- Duckworth AD, Buijze GA, Moran M, et al. Predictors of fracture following suspected injury to the scaphoid. *J Bone Joint Surg Br*. 2012;94:961-968.
- Duckworth AD, Ring D, McQueen MM. Assessment of the suspected fracture of the scaphoid. *J Bone Joint Surg Br*. 2011;93:713-719.
- Gabler C, Kukla C, Breitseher MJ, Trattig S, Vecsei V. Diagnosis of occult scaphoid fractures and other wrist injuries. Are repeated clinical examinations and plain radiographs still state of the art? *Langenbecks Arch Surg*. 2001;386:150-154.
- Gemme S, Tubbs R. What physical examination findings and diagnostic imaging modalities are most useful in the diagnosis of scaphoid fractures? *Ann Emerg Med*. 2015;65:308-309.
- Ghane MR, Rezaee-Zavareh MS, Emami-Meibodi MK, Dehghani V. How trustworthy are clinical examinations and plain radiographs for diagnosis of scaphoid fractures? *Trauma Mon*. 2016;21:23345.
- Gibney B, Murphy MC, Ahern DP, Hynes D, MacMahon PJ. Trapezium fracture: a common clinical mimic of scaphoid fracture. *Emerg Radiol*. 2019;26:531-540.
- Jenkins PJ, Slade K, Huntley JS, Robinson CM. A comparative analysis of the accuracy, diagnostic uncertainty and cost of imaging modalities in suspected scaphoid fractures. *Injury*. 2008;39:768-774.
- Karl JW, Swart E, Strauch RJ. Diagnosis of occult scaphoid fractures: a cost-effectiveness analysis. *J Bone Joint Surg Am*. 2015;97:1860-1868.
- Link TM. Osteoporosis imaging: state of the art and advanced imaging. *Radiology*. 2012;263:3-17.
- Low G, Raby N. Can follow-up radiography for acute scaphoid fracture still be considered a valid investigation? *Clin Radiol*. 2005;60:1106-1110.
- Machin E, Blackham J, Bengier J. Guidelines in emergency medicine department. GEMNet guideline: management of suspected scaphoid fractures in the emergency department. Available at: http://81.143.226.227/Medicine/Guidelines/RCEM%20-%20Royal%20College%20of%20Emergency%20Medicine/2013_09%20CEM7431%20Suspected%20Scaphoid%20Fractures.pdf. Accessed October 15, 2018.
- Mallee WH, Henny EP, van Dijk CN, Kamminga SP, van Enst WA, Kloen P. Clinical diagnostic evaluation for scaphoid fractures: a systematic review and meta-analysis. *J Hand Surg Am*. 2014;39:1683-1691.
- Mallee WH, Walenkamp MMJ, Mulders MAM, Goslings JC, Schep NWL. Detecting scaphoid fractures in wrist injury: a clinical decision rule. *Arch Orthop Trauma Surg*. 2020;140:575-581.
- Mallee WH, Wang J, Poolman RW, et al. Computed tomography versus magnetic resonance imaging versus bone scintigraphy for

- clinically suspected scaphoid fractures in patients with negative plain radiographs. *Cochrane Database Syst Rev.* 2015;2015(6): CD010023.
37. Manske SL, Zhu Y, Sandino S, Boyd SK. Human trabecular bone microarchitecture can be assessed independently of density with second generation HR-pQCT. *Bone.* 2015;79:213-221.
 38. Memarsadeghi M, Breitenseher MJ, Schaefer-Prokop C, et al. Occult scaphoid fractures: comparison of multidetector CT and MR imaging—initial experience. *Radiology.* 2006;240:169-176.
 39. Mueller TL, Stauber M, Kohler T, Eckstein F, Muller R, van Lenthe GH. Non-invasive bone competence analysis by high-resolution pQCT: an in vitro reproducibility study on structural and mechanical properties at the human radius. *Bone.* 2009;44:364-371.
 40. Nguyen Q, Chaudhry S, Sloan R, Bhoora I, Willard C. The clinical scaphoid fracture: early computed tomography as a practical approach. *Ann R Coll Surg Engl.* 2008;90:488-491.
 41. Parvizi J, Wayman J, Kelly P, Moran CG. Combining the clinical signs improves diagnosis of scaphoid fractures. A prospective study with follow-up. *J Hand Surg Br.* 1998;23:324-327.
 42. Pialat JB, Burghardt AJ, Sode M, Link TM, Majumdar S. Visual grading of motion induced image degradation in high resolution peripheral computed tomography: impact of image quality on measures of bone density and micro-architecture. *Bone.* 2012;50: 111-118.
 43. Pichler W, Windisch G, Schaffler G, Heidari N, Dorr K, Grechenig W. Computer-assisted 3-dimensional anthropometry of the scaphoid. *Orthopedics.* 2010;33:85-88.
 44. Rhemrev SJ, Beeres FJ, van Leerdam RH, Hogervorst M, Ring D. Clinical prediction rule for suspected scaphoid fractures: a prospective cohort study. *Injury.* 2010;41:1026-1030.
 45. Rhemrev SJ, de Zwart AD, Kingma LM, et al. Early computed tomography compared with bone scintigraphy in suspected scaphoid fractures. *Clin Nucl Med.* 2010;35:931-934.
 46. Rhemrev SJ, Ootes D, Beeres FJ, Meylaerts SA, Schipper IB. Current methods of diagnosis and treatment of scaphoid fractures. *Int J Emerg Med.* 2011;4:4.
 47. Ring D, Lozano-Calderon S. Imaging for suspected scaphoid fracture. *J Hand Surg Am.* 2008;33:954-957.
 48. Tiel-van Buul MM, van Beek EJ, Broekhuizen AH, Bakker AJ, Bos KE, van Royen EA. Radiography and scintigraphy of suspected scaphoid fracture. A long-term study in 160 patients. *J Bone Joint Surg Br.* 1993;75:61-65.
 49. Unay K, Gokcen B, Ozkan K, Poyanli O, Eceviz E. Examination tests predictive of bone injury in patients with clinically suspected occult scaphoid fracture. *Injury.* 2009;40:1265-1268.
 50. Yin ZG, Zhang JB, Kan SK, Wang XG. Diagnosing suspected scaphoid fractures: a systematic review and meta-analysis. *Clin Orthop Relat Res.* 2010;468:723-34.